

Tumour-Induced Osteomalacia in Metastatic Prostate Carcinoma

Sir,

A 61-year-old man presented with low backache and severe proximal muscle weakness of 2-year duration. He also had an increased urinary frequency for the past 3 years, and he was evaluated elsewhere and diagnosed to have adenocarcinoma of prostate based on an elevated prostate specific antigen and biopsy of gland. He received radiation therapy (30 Gy in 10 fractions) prior to visiting our centre. On examination, there was no bony deformity. He had significant proximal myopathy of lower limbs; there was no other focal neurological deficit. There was no history of fractures. The rest of the systemic examination was normal. His serum total prostate specific antigen was 1137 ng/ml. The radiograph of the lumbar spine demonstrated osteosclerotic vertebrae [Figure 1], and Technetium-99m methylene diphosphonate (MDP) scan revealed disseminated osseous metastasis [Figure 2]. A computed topography (CT) scan of the thorax, abdomen, and pelvis done elsewhere had shown the prostatic mass and right axillary lymphadenopathy. The biopsy from the axillary lymph node was reported as a metastatic acinar adenocarcinoma. Further evaluation for the cause of proximal myopathy demonstrated normal fasting corrected serum calcium (8.6 mg/dL) with low phosphate levels (1.4 mg/dL) and normal serum creatinine (0.8 mg/dL). He had an elevated alkaline phosphatase (551 U/L) with 25(OH) vitamin D of 17 ng/mL and a normal PTH (37 pg/mL). In addition, he had a low renal threshold of phosphate reabsorption (TmP/GFR 1.8 mg/dL). His FGF-23 level was markedly elevated (587 RU/mL), confirming the fibroblast growth factor 23 (FGF-23)-mediated phosphaturia and hypophosphatemic osteomalacia secondary to metastatic prostate adenocarcinoma.

He was subsequently initiated on phosphate supplementation and calcitriol. For the metastatic prostate cancer, he underwent bilateral orchidectomy and was later initiated on androgen biosynthesis inhibitor abiraterone along with prednisolone. As the patient had wished for follow-up at his hometown, a repeat FGF-23 level was not available.

Prostate cancer is the second most common urological malignancy associated with paraneoplastic syndromes. The endocrine paraneoplastic syndromes associated include syndrome of inappropriate antidiuretic hormone (SIADH), Cushing's syndrome, PTH-rP-mediated hypercalcaemia, and rarely tumour-induced osteomalacia.^[1,2] Tumour-induced osteomalacia (TIO), also known as oncogenic osteomalacia, occurs as a consequence of overproduction of FGF-23 by a tumour, resulting in several skeletal manifestations, which include osteomalacia in adults and rickets in children. FGF-23, through its action on sodium-dependent phosphate transport proteins NPT2A and NPT2C in the kidney, reduces tubular re-absorption of phosphate and in turn leads to low serum phosphate levels. FGF-23 also down-regulates renal 1,25(OH) vitamin D synthesis as well as PTH production and secretion.^[3] The down-regulation of 1,25(OH) vitamin D may also contribute to reduced intestinal absorption of phosphate.

The most common cause of oncogenic osteomalacia is mixed connective tissue types of mesenchymal tumours. The manifestations associated with TIO may also often be subtle and lead to significant time lag from symptom onset to diagnosis.^[4] Oncogenic osteomalacia was diagnosed in our patient only after metastatic prostate cancer was detected

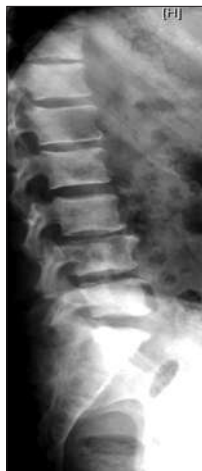

Figure 1: Radiograph of lumbar spine showing osteosclerotic vertebra

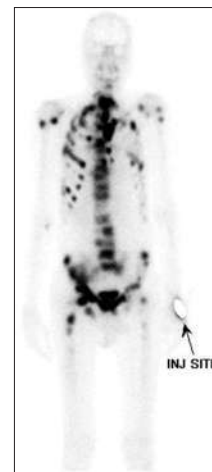


Figure 2: Technetium-99m methylene diphosphonate (MDP) scan showing disseminated osseous metastasis

and an initial bout of radiation therapy executed, clearly demonstrating the importance of being aware of the varied manifestations of both metastatic prostate cancer and symptom complex of TIO. Although commonly associated with small benign tumours, TIO can rarely be a secondary paraneoplastic manifestation of advanced metastatic cancers, including prostate cancer as seen in the present patient.

Financial support and sponsorship

Nil.

Conflicts of interest

There are no conflicts of interest.

Sreevatsa Tatachar, Rebecca John, Julie Hephzibah¹, Santhosh Kumar², Thomas V. Paul, Kripa Elizabeth Cherian

Departments of Endocrinology, ¹Nuclear Medicine and ²Urology, Christian Medical College, Vellore, Tamil Nadu, India

Address for correspondence: Dr. Kripa Elizabeth Cherian, Department of Endocrinology, Diabetes and Metabolism, Christian Medical College, Vellore, Tamil Nadu -632 004, India.
E-mail: kripaec@gmail.com

REFERENCES

1. Hong MK, Kong J, Namdarian B, Longano A, Grummet J, Hovens CM, *et al.* Paraneoplastic syndromes in prostate cancer. *Nat Rev Urol* 2010;7:681-92.
2. Layman AAK, Joshi S, Shah S. Metastatic prostate cancer presenting as tumour-induced osteomalacia. *BMJ Case Rep* 2019;16;12:e229434.
3. Minisola S, Peacock M, Fukumoto S, Cipriani C, Pepe J, Tella SH, *et al.* Tumour-induced osteomalacia. *Nat Rev Dis Primers* 2017;3:17044.
4. Chong WH, Molinolo AA, Chen CC, Collins MT. Tumour-induced osteomalacia. *Endocr Relat Cancer* 2011;18:R53-77.

Submitted: 21-Mar-2023

Revised: 12-Apr-2023

Accepted: 26-Apr-2023

Published: 28-Aug-2023

This is an open access journal, and articles are distributed under the terms of the Creative Commons Attribution-NonCommercial-ShareAlike 4.0 License, which allows others to remix, tweak, and build upon the work non-commercially, as long as appropriate credit is given and the new creations are licensed under the identical terms.

Access this article online

Quick Response Code:



Website:

<https://journals.lww.com/indjem/>

DOI:

10.4103/ijem.ijem_125_23

How to cite this article: Tatachar S, John R, Hephzibah J, Kumar S, Paul TV, Cherian KE. Tumour-induced osteomalacia in metastatic prostate carcinoma. *Indian J Endocr Metab* 2023;27:368-9.

© 2023 Indian Journal of Endocrinology and Metabolism | Published by Wolters Kluwer - Medknow