

# Impact of teriparatide therapy in Indian postmenopausal women with osteoporosis with regard to DXA-derived parameters

Nandipati Venkata Sandeep, Aneez Joseph, Kripa Elizabeth Cherian, Nitin Kapoor and Thomas V Paul 

*Ther Adv Endocrinol Metab*

2022, Vol. 13: 1–8

DOI: 10.1177/  
20420188221112903

© The Author(s), 2022.  
Article reuse guidelines:  
[sagepub.com/journals-permissions](https://sagepub.com/journals-permissions)

## Abstract

**Background:** There is paucity of literature on the impact of teriparatide on hip geometry and bone microarchitecture globally and none from the Indian subcontinent. This study examined the outcome of teriparatide therapy on vertebral fractures, bone mineral density (BMD), hip structural analysis (HSA), and trabecular bone score (TBS) in Indian postmenopausal women with severe osteoporosis.

**Methodology:** Ambulatory postmenopausal women above the age of 50 years with either severe osteoporosis or vertebral fractures, or both, were recruited. All patients received cholecalciferol (2000 IU/day), calcium carbonate (elemental calcium 1 g/day), and teriparatide (20 mcg subcutaneously/day) for 24 months. Baseline bone biochemistry, BMD, TBS, and HSA were assessed and repeated after 24 months of therapy. Incident vertebral and nonvertebral fractures were also studied.

**Results:** A total of 51 postmenopausal women with mean (SD) age of 65.7(8.6) years, and mean (SD) body mass index of 22.7 (3.5) kg/m<sup>2</sup> were recruited in this study. Vertebral fractures were present in 74.5% (38/51) at baseline. Following teriparatide therapy, significant improvement was observed in the BMD (g/cm<sup>3</sup>) at both the lumbar spine (0.706–0.758:  $p < 0.001$ ) and femoral neck (0.551–0.579:  $p = 0.047$ ) as well as the TBS (1.160–1.271:  $p < 0.001$ ). Most indices of proximal hip geometry also showed significant improvement following teriparatide therapy at 24 months. Incident vertebral fractures were noted in only 7.8% (4/51) of participants, while 92% (47/51) of participants did not develop any new vertebral fractures on follow-up.

**Conclusion:** In South Indian postmenopausal women with either severe osteoporosis or vertebral fractures, or both, teriparatide was effective in improving the bone mineral parameters and bone quality.

**Keywords:** hip geometry, osteoporosis, teriparatide, trabecular bone score

Received: 4 September 2021; revised manuscript accepted: 24 June 2022.

## Introduction

Osteoporosis is emerging as a major public health problem, affecting up to 50% of postmenopausal women in different community-based studies.<sup>1,2</sup> Bone loss in postmenopausal women results from estrogen deficiency due to cessation of ovarian function at menopause. This leads to alteration of the bone remodeling cycle, with increased bone resorption. In the early phase, there is a

predominant loss of trabecular bone. After 4–8 years, there is a slower but persistent loss of both trabecular and cortical bone, which occurs chiefly due to reduced bone formation.<sup>1</sup> This is the phase of age-related bone loss, and it is the only phase that occurs in men. The prevalence of osteoporosis increases with advancing age and this is compounded by suboptimal awareness of the condition that exists among both physicians and patients.<sup>3,4</sup>

Correspondence to:

**Thomas V Paul**  
Professor & Head,  
Department of  
Endocrinology, Diabetes  
& Metabolism, Christian  
Medical College, Vellore,  
Ida Scudder Road, Vellore,  
632004, India.  
[thomasvpaul@yahoo.com](mailto:thomasvpaul@yahoo.com)

**Nandipati Venkata Sandeep**  
**Aneez Joseph**  
**Kripa Elizabeth Cherian**  
**Nitin Kapoor**  
Department of  
Endocrinology, Diabetes  
& Metabolism, Christian  
Medical College, Vellore,  
Vellore, India

Osteoporosis predisposes affected individuals to fragility fractures and this adversely affects their physical mobility and leads to an increased mortality risk among them. Globally, about 20% of women with hip fractures succumb within a year and about 50% of them remain permanently dependent for their activities of daily living.<sup>5</sup> In addition, vertebral fractures are also associated with an increased morbidity. The key risk factors for the development of osteoporosis include low peak bone mass, history of parental hip fracture, glucocorticoid use, and inflammatory conditions like rheumatoid arthritis. This may be further compounded by poor calcium intake and vitamin D deficiency in many Indian settings.<sup>1</sup>

Parathyroid (PTH) analogs are one of the key anabolic agents approved for the treatment of osteoporosis.<sup>6</sup> Chronic infusions of PTH analogs are primarily catabolic for the bone, but the intermittent subcutaneous injections of the same lead to a net anabolic effect, particularly in trabecular bone. Teriparatide (PTH 1-34) has been used for the management of postmenopausal osteoporosis for about two decades and is recommended for use in those with severe osteoporosis, those non-responsive to anti-resorptive medications, and in those with multiple fractures.<sup>7</sup> Teriparatide has a peak effect on bone formation (by stimulating the proliferation and activity of osteoblasts) after 6–12 months of exposure.

Although areal bone mineral density (BMD) is the most widely used method to evaluate bone mass, it suffers limitations in assessing the proximal femur owing to its 3D geometry, its low spatial resolution, and the 2D imaging approach.<sup>8</sup> Trabecular bone score (TBS) is a dual energy X-ray absorptiometry (DXA)-derived parameter, which is a grayscale textural index that can be extracted from lumbar spine images. It is an integrated measure of skeletal microarchitecture and has been shown to predict fracture incidence independent of a BMD measurement and clinical risk factors. Hip structural analysis (HSA) by DXA is another parameter that assesses indices pertaining to proximal hip geometry based on archived DXA images of the proximal hip.<sup>8–10</sup> However, there are no data on the effect of teriparatide on TBS and HSA in the Indian context.

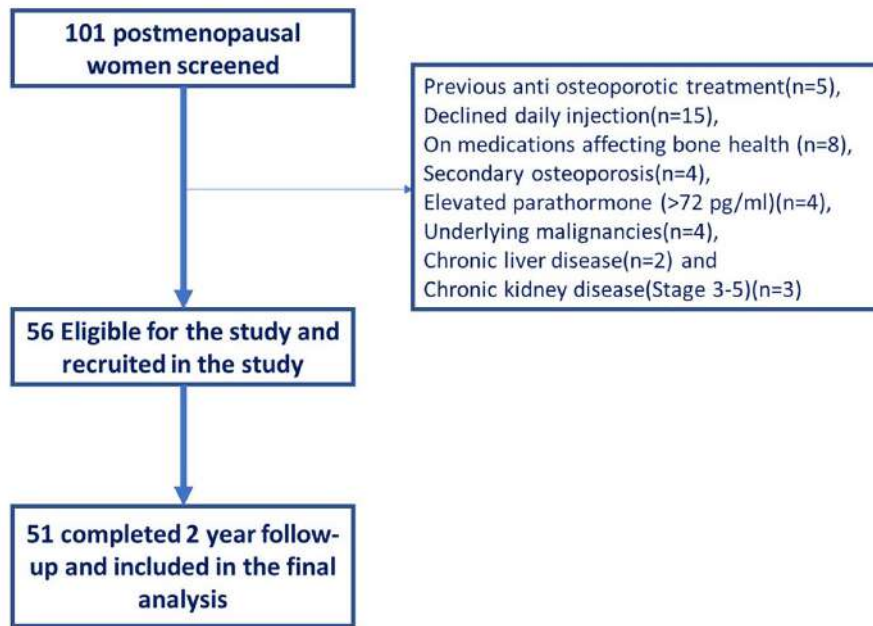
In the current study, the authors aim to evaluate the impact of teriparatide on incident/worsening

vertebral fractures, BMD, bone microarchitecture (TBS), and proximal hip geometry (HSA) in south Indian postmenopausal women with osteoporosis.

### Methodology

This was an observational prospective community-based study of 30 months' duration from 1 March 2018 to 30 September 2020 in a 3000 bedded multispecialty university-affiliated teaching hospital in southern India. Ambulatory postmenopausal women >50 years with either severe osteoporosis or vertebral fractures, or both, and willing for daily subcutaneous injections were included. A total of 101 postmenopausal women >50 years of age with osteoporosis were screened from a single village in Vellore district in southern India. Among them, those on previous anti-osteoporotic treatment ( $n = 5$ ), those who declined daily injection ( $n = 15$ ), women on medications affecting bone health (except calcium and vitamin D supplements) ( $n = 8$ ), presence of secondary osteoporosis ( $n = 4$ ), elevated parathormone ( $>72$  pg/ml) ( $n = 4$ ), those with underlying malignancies ( $n = 4$ ), chronic liver disease ( $n = 2$ ), and women with chronic kidney disease (Stages 3–5) ( $n = 3$ ) were excluded from the study. After preliminary screening, 56 women were found to be eligible and 51 of them completed the 2-year follow-up and were included for final analysis (Figure 1).

Assessment of participants comprised clinical history and examination pertaining to anthropometry. Fasting (overnight for 8 h) venous blood samples were collected for the measurement of serum calcium (N: 8.3–10.4 mg/dl), phosphate (N: 2.5–4.5 mg/dl), alkaline phosphatase (N: 40–125 U/l), albumin (N: 3.5–5.0 g/dl), creatinine (N: 0.6–1.4 mg/dl), and 25-hydroxy vitamin D (N: 30–75 ng/ml). Blood calcium, phosphate, albumin, creatinine, and alkaline phosphatase were measured using colorimetric method with Beckman Coulter (Beckman Coulter AU 5800). An iced sample for intact parathormone (iPTH) was collected and estimated by chemiluminescence assay (Advia Centaur XPT immunoassay system), and 25-hydroxyvitamin D (vitamin D) was measured using electrochemiluminescence assay (Roche Cobas 6000–Immunoassay system). Bone turnover markers, plasma CTX (N: 226–1088 pg/ml), and P1NP (N: 16–73.9 ng/ml) were measured using electrochemiluminescence



**Figure 1.** Recruitment of study subjects.

immunoassay (ECLIA) on a Roche Elecsys Modular E170 analyzer.

BMD was assessed using Hologic DXA scan (Discovery A) at the lumbar spine (L1–L4; CV: 1–2%) and the neck of femur (CV: 2–3%), and osteoporosis was defined as a BMD T-score of  $\leq 2.5$  at either of these sites. Severe osteoporosis was defined as T-score of  $\leq 3.5$  or the presence of a fragility fracture with a T-score of  $\leq 2.5$ . DXA scan was also used to determine new/incident vertebral fractures (vertebral fracture analysis), bone microarchitecture (TBS), and hip geometry (HSA), determined by using the Hologic database. Genant's classification (vertebral height loss of 20–25% – mild; 25–40% – moderate; >40% severe) was used to classify vertebral fractures and only moderate to severe vertebral fractures were considered significant in this study. Incident fractures were defined as the presence of a new onset (moderate/severe) fracture or worsening of an existing mild fracture to moderate/severe or a moderate fracture to severe, during the follow-up period. TBS (L1–L4) measurements were performed using TBS iNsight Software version 3 (Med-Imaps, Bordeaux, France). Degraded bone microarchitecture was defined by a TBS value that was  $< 1.200$ .<sup>8</sup> The CV of the BMD measurement at lumbar spine was 0.8%, at femoral neck it was 1.0%, and for TBS it was 0.8%.

Proximal hip geometry (CV: 1–2%) was assessed at three sites, namely, the narrow neck (NN), the intertrochanteric (IT) region, and the femoral shaft (FS) and four parameters were assessed at each of these sites: cross-sectional area (CSA), cross-sectional moment of inertia (CSMI), section modulus (Z), and buckling ratio (BR). Protection from fractures was indicated by an increase in CSA, CSMI, and section modulus (Z) or by a decrease in BR.<sup>10</sup>

All participants received cholecalciferol (2000 IU/day), calcium carbonate (elemental calcium 1 g/day), and teriparatide (20 mcg subcutaneously/day) for 24 months. Those study participants who were found to have vitamin D deficiency ( $< 20$  ng/ml) were treated adequately (cholecalciferol 60,000 IU once a week) for 8 weeks before initiating teriparatide.

Data were analyzed using SPSS v 24.0 (SPSS IBM Corp, USA). Continuous variables were expressed as mean and SD, and categorical variables were expressed as frequencies and percentages. The differences in means of continuous variables before and after the intervention were compared using paired *t* test. The differences in proportions were compared using the Pearson's chi-square test. For all comparisons, a two-tailed *p* value of 0.05 was considered statistically significant.

**Table 1.** Baseline characteristics.

Parameter studied	Baseline mean (SD) <i>N</i> = 51
Age (years)	65.7 (8.6)
Height (cm)	149.5(4.9)
BMI (kg/m <sup>2</sup> )	22.7 (3.5)
Years since menopause	17.2 (8.7)
BMI, body mass index; PTH, parathormone.	

**Table 2.** Bone mineral parameters at baseline and follow-up.

Parameter (n) <i>N</i> = 51	Baseline mean (SD)	Follow-up (after 24 months) mean (SD)	<i>p</i> value
Femoral neck BMD (g/cm <sup>2</sup> )	0.551 (0.071)	0.579 (0.061)	0.035
Lumbar spine BMD (g/cm <sup>2</sup> )	0.706 (0.091)	0.758 (0.106)	<0.001
TBS	1.160 (0.11)	1.271 (0.12)	<0.001
25 (OH) vitamin D (ng/ml)	30.1 (2.5)	31.7 (6.7)	0.11
Creatinine (mg/dl)	0.7 (0.1)	0.71 (0.1)	0.61
PTH (pg/ml)	40.9 (10.8)	–	–
P1NP (ng/ml)	31.14 (6.90)	125.96 (30.47)	<0.001
CTX (pg/ml)	301.63 (83.43)	727.08 (42.31)	<0.001
BMD, body mineral density; CTX, C-terminal cross-linked telopeptide; P1NP, procollagen type 1 N-terminal propeptide; TBS, trabecular bone score.			

## Results

The mean (SD) age and body mass index of the study participants (*N* = 51) was 65.7 (8.6) years and 22.7 (3.5) kg/m<sup>2</sup>. Vertebral fractures (moderate and severe) were present in 74.4% (38/51) at baseline; 11 had a history of peripheral nonvertebral fractures (including 3 patients with hip fractures). Other baseline characteristics are summarized in Table 1. Incident/worsening of vertebral fractures was noted in 7.8% participants, while no new nonvertebral fractures were observed during follow-up.

Significant increment [mean (SD)] in lumbar spine BMD [baseline 0.706 (0.091) to follow-up 0.758 (0.106) gm/cm<sup>2</sup>; *p* < 0.001] and femoral neck BMD [baseline 0.551 (0.071) to follow-up

0.579 (0.061) gm/cm<sup>2</sup>; *p* = 0.047] was noted after intervention. The increment noted was 7.3% and 5.1% at the lumbar spine and femoral neck, respectively. Similarly, TBS also significantly improved after teriparatide (9.6%) at 2 years of follow-up [baseline 1.160 (0.110) to follow-up 1.271 (0.120); *p* < 0.001]. Procollagen type 1 N-terminal propeptide (P1NP) and C-terminal cross-linked telopeptide (CTX) levels increased significantly following teriparatide therapy (Table 2).

The parameters of HSA are summarized in Table 3. Significant improvement (*p* < 0.01) was seen in most of the HSA parameters at the intertrochanteric region and the femoral shaft. At the narrow neck region, the only parameter which showed improvement was the BR [13.5 (2.5)–12.7 (2.1); *p* = 0.014] (Table 3).

## Discussion

This is the first prospective study from India to study the impact of anabolic therapy on bone microarchitecture, hip geometry, and incident fragility fractures. In this study, vertebral fractures were present in three-fourths of the study participants at baseline. At the end of 2 years, incident fragility fractures of the spine were noted in 7% of the participants. Following teriparatide therapy, the improvement in bone microarchitecture was more robust compared with BMD at both the LS and FN. Most indices of proximal hip geometry (HSA) also showed significant improvement following teriparatide therapy, at 24 months.

Parathyroid analogs are one of the key anabolic agents approved for the treatment of osteoporosis.<sup>6</sup> It works by enhancing the action of osteoblasts and improving bone strength. It has a peak effect on bone formation (by stimulating the proliferation and activity of osteoblasts) after 6–12 months of exposure. Teriparatide also works to improve the number and thickness of trabeculae and increases trabecular connectivity. Teriparatide (PTH 1–34) has been used for the management of postmenopausal osteoporosis for about two decades and is recommended for use in those with severe osteoporosis, those nonresponsive to anti-resorptive medications, and in those with multiple fractures.<sup>7</sup> The beneficial effect of vitamin D replacement along with calcium in fracture reduction in the present study is difficult to conclude due to the small sample size and the absence of prior Indian studies in this regard. Nevertheless,

**Table 3.** Hip structural analysis at baseline and follow-up.

Parameter <i>N</i> = 51	Baseline mean (SD)	After 24 months of teriparatide mean (SD)	<i>p</i> value
Hip structural analysis at the intertrochanter region			
CSA (cm <sup>2</sup> )	3.51 (0.53)	3.61 (0.49)	<b>0.001</b>
CSMI (cm <sup>4</sup> )	8.42 (1.61)	8.89 (1.72)	<b>0.005</b>
Z (cm <sup>3</sup> )	2.77 (0.51)	2.91 (0.48)	<b>0.001</b>
BR	10.8 (2.3)	10.5 (2.0)	0.122
Hip structural analysis at the femoral shaft region			
CSA (cm <sup>2</sup> )	3.04 (0.4)	3.08 (0.36)	0.531
CSMI (cm <sup>4</sup> )	2.46 (0.5)	2.52 (0.52)	<b>0.026</b>
Z (cm <sup>3</sup> )	1.67 (0.25)	1.69 (0.24)	0.057
BR	3.8 (0.8)	3.8 (0.7)	0.846
Hip structural analysis at narrow neck region			
CSA (cm <sup>2</sup> )	2.00 (0.22)	2.02 (0.21)	0.428
CSMI (cm <sup>4</sup> )	1.51 (0.28)	1.49 (0.30)	0.418
Z (cm <sup>3</sup> )	0.87 (0.13)	0.86 (0.11)	0.777
BR	13.5 (2.5)	12.7 (2.1)	<b>0.014</b>
BR, buckling ratio; CSA, cross-sectional area; CSMI, cross-sectional moment of inertia; Z, section modulus. Values in bold are statistically significant.			

previous meta-analyses of vitamin D with or without calcium for the prevention of fragility fractures have reported conflicting results, with some showing favorable effects while others displaying no beneficial effects.<sup>11</sup>

In the present study, despite including individuals with either severe osteoporosis or prevalent vertebral fractures, or both, who were at the high risk of sustaining subsequent osteoporotic fractures, the authors noted a remarkable increase in BMD, bone microarchitecture, and proximal hip geometry as well as a significant reduction in the occurrence of incident fragility fractures. It is true that there were 7.8% of women with fracture after teriparatide therapy and the exact reason for this could not be ascertained. It may be reinstated that they were elderly women with severe osteoporosis with prevalent fractures, which by itself is a risk factor for future fragility fractures.

In the landmark, fracture prevention trial (FPT) which was a randomized, double-blind,

placebo-controlled study that evaluated the use of daily teriparatide 20 mcg for a total duration of 19 months in postmenopausal women with prior fractures, a similar incidence of vertebral fractures has been reported in the treatment arm. The incident/worsening vertebral fractures after teriparatide in the current study was 7% and this was akin to the intervention arm of the FPT where incident fractures were noted to occur in 5% of the study participants. In the same trial (FPT), 14% of participants in the placebo arm had sustained fractures.<sup>12</sup>

The incidence of nonvertebral fractures in the FPT was 5.5% and 2.6% for placebo and teriparatide, respectively, in contrast to no new nonvertebral fracture in our study participants. This was probably due to a relatively smaller sample size. In the Direct Assessment of Non-Vertebral Fractures in Community Experience (DANCE) study, which evaluated 4085 men and women treated with teriparatide for 24 months, the incidence of new nonvertebral fractures during the treatment

period was 3.84%, 4.07%, and 1.85% for all female and male participants, respectively.<sup>13</sup>

In the 18-month data from the European Forsteo Observational Study (EFOS), the incidence of vertebral and nonvertebral fractures in teriparatide-treated postmenopausal women with severe osteoporosis was 3.8% and 7.2%, respectively. A similar incidence was noted in another study by Lindsay *et al.*<sup>14</sup> (1.2% and 2.8%).<sup>15</sup>

In the 24-month results from the extended Forsteo Observational Study (ExFOS), the incidence of vertebral and nonvertebral fractures in teriparatide-treated individuals (including postmenopausal women, men, and glucocorticoid-induced osteoporosis) was 1.7% and 6.7%, respectively.<sup>16</sup> In a large observational post marketing surveillance (PMS) study in Japan, including patients with high risk of fractures treated with teriparatide for 24 months, the incidence of new vertebral or nonvertebral fracture during the study was 2.9% and 4.6%, respectively.<sup>17</sup>

In the EuroFORS study, which included 84 treatment naïve individuals with postmenopausal osteoporosis, 24 months of teriparatide therapy led to an increment in the BMD at the lumbar spine and femoral neck by +13.1% and +4.8%, respectively.<sup>18</sup> The increment noted in the current study was 7.3% and 5.1%, respectively. Miyauchi *et al.*<sup>19</sup> noted a significant increment in the BMD at lumbar spine (+13.4%) and femoral neck (+3.2%) among 96 Japanese men and women with low bone mass treated with 20 mcg of teriparatide. In the DATA extension study, wherein 31 (of the total 94 postmenopausal women with osteoporosis) received teriparatide for a total duration of 24 months, increments in lumbar spine BMD and femoral neck BMD were  $(9.5 \pm 5.9\%)$  and  $(2.8 \pm 3.9\%)$ , respectively.<sup>20</sup> Similar increment has been documented in other studies in the Caucasian population.<sup>21,22</sup>

The reduction in incident fractures observed in our study is similar to previously published data, although the increment in BMD is not as robust as has been documented by other studies. This has been noted even with zoledronic acid and may be related to an ethnic variation in the peak bone mass.<sup>23</sup> The anabolic effect of teriparatide was better reflected in the proximal hip geometry than in the femoral neck BMD.

In the DATA extension study, after 24 months of therapy, TBS increased by  $2.7 \pm 4.7\%$  in women treated with teriparatide monotherapy ( $p = 0.009$  versus baseline).<sup>20</sup> In an open-label, multicenter study by Guenther *et al.*, where 82 women were treated with teriparatide for 2 years, the spine TBS increased by +4.3% ( $p < 0.001$ ). The increment in TBS in our study was 9.6% and is probably a better indicator of improvement in bone health compared with BMD, as it correlates well with the decline in incident fractures.<sup>24</sup>

In a study by Uusi-Rasi K *et al.* 558 postmenopausal women with osteoporosis (participants from FPT), both mechanical strength and stability (as suggested by increase in CSA and section modulus as well as decrease in BR) improved at the femoral neck and intertrochanteric sites, but not at the proximal femoral shaft following teriparatide therapy. This is similar to the findings reported in the present study.<sup>25</sup>

Following administration of an anabolic agent, an increase in bone formation markers is expected, which is further followed by an increase in bone resorption.<sup>26</sup> In the current study, both procollagen type 1 N-terminal propeptide (P1NP) and C-terminal cross-linked telopeptide (CTX) levels increased remarkably following teriparatide therapy.

Although it would have been ideal to include controls in this study to compare the efficacy of teriparatide, we did not do so as it would be ethically incorrect to devoid patients with severe osteoporosis of this anti-osteoporotic therapy. Moreover, these patients would be at a high risk of developing life-threatening fractures and hence a placebo as an injection would not be ethically feasible. Furthermore, the bone mineral parameters of each patient are considered to be a control for that subject after teriparatide therapy during follow-up. Understanding the need for comparison, we have compared our results with other published papers from our center/similar ethnic population with other standard therapies.

The key strengths of this study include its prospective nature and the assessment of vertebral fractures. Moreover, this is the first study from India to assess the effect of teriparatide on bone microarchitecture and proximal hip geometry. The small sample size is the key limitation of this study. There was no data on serum PTH during follow-up cap-

tured during this study. Further prospective studies are required to validate these findings.

## Conclusion

In South Indian postmenopausal women with either severe osteoporosis or vertebral fractures, or both, teriparatide was effective in improving the bone mineral parameters. Teriparatide therapy also improved the BMD, TBS, and many indices of proximal hip geometry.

## Declarations

### *Ethics approval and consent to participate*

This study was approved by the Institutional Review Board of the Christian Medical College and Hospital (11260/18), Vellore. All participants provided written informed consent and were offered treatment as part of routine medical care.

### *Consent for publication*

Not applicable.

### *Author contributions*

**Nandipati Venkata Sandeep:** Data curation; Writing – original draft.

**Aneez Joseph:** Data curation; Writing – original draft.

**Kripa Elizabeth Cherian:** Conceptualization; Supervision; Writing – review & editing.

**Nitin Kapoor:** Conceptualization; Supervision; Writing – review & editing.

**Thomas V Paul:** Conceptualization; Supervision; Writing – review & editing.

### *Acknowledgements*

None.

### *Funding*

The authors disclosed receipt of the following financial support for the research, authorship, and/or publication of this article: Teriparatide, calcium, and cholecalciferol were provided by the Department of Endocrinology, Diabetes and Metabolism, Christian Medical College, Vellore, India.

### *Competing interests*

The authors declared no potential conflicts of interest with respect to the research, authorship, and/or publication of this article.

### *Availability of data and materials*

Not applicable.

## ORCID iD

Thomas V Paul  <https://orcid.org/0000-0003-3315-341X>

## References

1. Khadilkar AV and Mandlik RM. Epidemiology and treatment of osteoporosis in women: an Indian perspective. *Int J Womens Health* 2015; 7: 841–850
2. Binu AJ, Cherian KE, Kapoor N, *et al.* Bone health after fifth decade in rural ambulatory South Indian postmenopausal women. *Indian J Community Med* 2019; 44: 205–208.
3. Senthilraja M, Cherian KE, Jebasingh FK, *et al.* Osteoporosis knowledge and beliefs among postmenopausal women: a cross-sectional study from a teaching hospital in Southern India. *J Family Med Prim Care* 2019; 8: 1374–1378.
4. Thakur P, Kuriakose C, Cherian KE, *et al.* Knowledge gap regarding osteoporosis among medical professionals in Southern India. *J Eval Clin Pract* 2020; 26: 272–280.
5. Paul TV, Selvan SA, Asha HS, *et al.* Hypovitaminosis D and other risk factors of femoral neck fracture in South Indian postmenopausal women: a pilot study. *J Clin Diagn Res* 2015; 9: OC19–OC22.
6. Chen CH, Elsalrawy AH, Ish-Shalom S, *et al.* The effect of teriparatide treatment on the risk of fragility fractures in postmenopausal women with osteoporosis: results from the Asian and Latin America Fracture Observational Study (ALAFOS). *Calcif Tissue Int* 2022; 110: 74–86.
7. Bhadada SK, Chadha M, Sriram U, *et al.* The Indian Society for Bone and Mineral Research (ISBMR) position statement for the diagnosis and treatment of osteoporosis in adults. *Arch Osteoporos* 2021; 16: 102.
8. Rajan R, Cherian KE, Kapoor N, *et al.* Trabecular bone score: an emerging tool in the management of osteoporosis. *Indian J Endocrinol Metab* 2020; 24: 237–243.
9. Paul J, Devarapalli V, Johnson JT, *et al.* Do proximal hip geometry, trabecular microarchitecture, and prevalent vertebral fractures differ in postmenopausal women with type 2 diabetes mellitus? A cross-sectional study from a teaching hospital in southern India. *Osteoporos Int* 2021; 32: 1585–1593.

10. Beck TJ and Broy SB. Measurement of hip geometry-technical background. *J Clin Densitom* 2015; 18: 331–337.
11. Yao P, Bennett D, Mafham M, *et al.* Vitamin D and calcium for the prevention of fracture: a systematic review and meta-analysis. *JAMA Netw Open* 2019; 2: e1917789.
12. Neer RM, Arnaud CD, Zanchetta JR, *et al.* Effect of parathyroid hormone (1-34) on fractures and bone mineral density in postmenopausal women with osteoporosis. *N Engl J Med* 2001; 344: 1434–1441.
13. Silverman S, Miller P, Sebba A, *et al.* The Direct Assessment of Nonvertebral Fractures in Community Experience (DANCE) Study: 2-year nonvertebral fragility fracture results. *Osteoporos Int* 2013; 24: 2309–2317.
14. Lindsay R, Miller P, Pohl G, *et al.* Relationship between duration of teriparatide therapy and clinical outcomes in postmenopausal women with osteoporosis. *Osteoporos Int* 2009; 20: 943–948.
15. Langdahl BL, Rajzbaum G, Jakob F, *et al.* Reduction in fracture rate and back pain and increased quality of life in postmenopausal women treated with teriparatide: 18-month data from the European Forsteo Observational Study (EFOS). *Calcif Tissue Int* 2009; 85: 484–493.
16. Langdahl BL, Ljunggren Ö, Benhamou CL, *et al.* Fracture rate, quality of life and back pain in patients with osteoporosis treated with teriparatide: 24-month results from the Extended Forsteo Observational Study (ExFOS). *Calcif Tissue Int* 2016; 99: 259–271.
17. Nishikawa A, Ishida T, Taketsuna M, *et al.* Safety and effectiveness of daily teriparatide in a prospective observational study in patients with osteoporosis at high risk of fracture in Japan: final report. *Clin Interv Aging* 2016; 11: 913–925.
18. Obermayer-Pietsch BM, Marin F, McCloskey EV, *et al.* Effects of two years of daily teriparatide treatment on BMD in postmenopausal women with severe osteoporosis with and without prior antiresorptive treatment. *J Bone Miner Res* 2008; 23: 1591–1600.
19. Miyauchi A, Matsumoto T, Sugimoto T, *et al.* Effects of teriparatide on bone mineral density and bone turnover markers in Japanese subjects with osteoporosis at high risk of fracture in a 24-month clinical study: 12-month, randomized, placebo-controlled, double-blind and 12-month open-label phases. *Bone* 2010; 47: 493–502.
20. Leder BZ, Tsai JN, Uihlein AV, *et al.* Two years of denosumab and teriparatide administration in postmenopausal women with osteoporosis (The DATA Extension Study): a randomized controlled trial. *J Clin Endocrinol Metab* 2014; 99: 1694–1700.
21. Cosman F, Nieves JW, Zion M, *et al.* Daily or cyclical teriparatide treatment in women with osteoporosis on no prior therapy and women on alendronate. *J Clin Endocrinol Metab* 2015; 100: 2769–2776.
22. Stepan JJ, Burr DB, Li J, *et al.* Histomorphometric changes by teriparatide in alendronate-pretreated women with osteoporosis. *Osteoporos Int* 2010; 21: 2027–2036.
23. Sooragonda B, Cherian KE, Jebasingh FK, *et al.* Longitudinal changes in bone mineral density and trabecular bone score following yearly zoledronic acid infusion in postmenopausal osteoporosis-a retrospective-prospective study from Southern India. *Arch Osteoporos* 2019; 14: 79.
24. Guenther B, Popp Albrecht W, Stoll D, *et al.* Beneficial effects of PTH on spine bone mineral density (BMD) and microarchitecture (TBS) parameters in postmenopausal women with osteoporosis: a 2-year study. Abstracts of the IOF-ECCEO12 European Congress on Osteoporosis and Osteoarthritis, March 21–24, 2012 and the 2nd IOF-ESCEO Pre-clinical Symposium, March 23–24, 2012, Bordeaux, France. *Osteoporos Int* 2012; 23 (Suppl. 2): 332–335.
25. Uusi-Rasi K, Semanick LM, Zanchetta JR, *et al.* Effects of teriparatide [rhPTH (1-34)] treatment on structural geometry of the proximal femur in elderly osteoporotic women. *Bone* 2005; 36: 948–958.
26. Shetty S, Kapoor N, Bondu JD, *et al.* Bone turnover markers: emerging tool in the management of osteoporosis. *Indian J Endocrinol Metab* 2016; 20: 846–852.