

Title

The Clinical and Laboratory Profile of Primary Hyperparathyroidism in India

Authors:

- * Nihal Thomas, Professor,**
- * Thomas V Paul, Assistant Professor**

*** Department of Endocrinology, Diabetes & Metabolism,
Christian Medical College, Vellore – 632 004.
India.**

Corresponding Author:

**Dr. Nihal Thomas, MD.,MNAMS(Endo).,FRACP(Endo).,
Professor,
Department of Endocrinology, Diabetes & Metabolism,
Christian Medical College, Vellore – 632 004.
India.**

E-mail: nihal_thomas@yahoo.com

Tel: +91-416-2282694

Fax: +91-416-4203570

The Clinical and Laboratory Profile of Primary Hyperparathyroidism in India

Introduction

Hypercalcemia has a number of causes, but in real life, the differential diagnosis is limited to only a few disorders. Following evaluation, primary hyperparathyroidism and malignancy are eventually the most common causes for hypercalcemia. Thus, a judicious approach is needed to diagnose the cause of hypercalcemia which includes a cost effective spectrum of preliminary investigations. Only when they fail to reveal the aetiology, a further and more detailed work up is required (1).

The Indian patient with hyperparathyroidism has a wide range of clinical presentations with a spectrum ranging from bone disease, stone disease to an asymptomatic state. Symptomatic disease and large parathyroid adenomas are particularly common in the Indian subcontinent (2). They have been attributed to a higher prevalence of vitamin D deficiency present in Indian population (3). Osteitis fibrosa cystica, a classical form of parathyroid bone disease traditionally attributed to renal failure is not an unusual presentation in our country, though it has become uncommon in the western world (4).

Clinical presentation

The mean age of presentation in subjects with hyperparathyroidism tends to be lower in this part of the continent when compared to a western population. Females are affected more often than men. The most common presenting symptoms are bone pain, recurrent renal stones, fatigue, proximal muscle weakness and neuropsychiatric

symptoms like depression, irritability and emotional lability (5,6). Other clinical features include recurrent fractures and brown tumors (including long bones and flat bones like facial bones) at various sites (7).

Hyperparathyroidism has also been detected where in the initial symptom was abdominal pain due to recurrent acute pancreatitis. It has been questioned as to whether hyperparathyroidism causes pancreatitis or as to whether it is an epiphenomenon. However, recent evidence has shown that it is an important presentation in the Indian populations clear cut evidence also points to more severe hypercalcemia in those with pancreatic disease when compared to those without pancreatic disease and hyperparathyroidism (8). The clinical features and biochemistry of chronic pancreatitis secondary to hyperparathyroidism have been compared with subjects with alcoholic and idiopathic varieties of pancreatitis.

Renal colic, bone disease, a palpable neck mass and psychiatric abnormalities were more commonly seen in subjects with pancreatitis and primary hyperparathyroidism (9) than in those with milder parathyroid disease. In case of associated vitamin D deficiency, additional features of osteomalacia or rickets like deformities and fractures are evident. Patients with vitamin D deficiency usually develop features of hungry bone disease like severe hypocalcemia following surgery (2). A palpable neck mass is not uncommon even in those with benign parathyroid disease.

Presentation with a red eye (Fig 1), secondary to hypercalcemia (10) with or without sclerosing keratitis is a possibility. Primary hyperparathyroidism is detected as a part of routine screening (asymptomatic) when a work up is done either in post

menopausal women or in patients with Multiple Endocrine Neoplasia (MEN) type 1 or 2A. Those women presenting with asymptomatic disease in a menopause are a minority in contrast to Western databases, where the majority of parathyroid disease that is seen occurs in postmenopausal asymptomatic women

Radiological features include osteitis fibrosa cystica (Fig 2 & 3), subperiosteal resorption of phalanges and the pubic rami and brown tumours. A salt & pepper appearance of the skull may be seen. Features of osteomalacia like Looser's zones are observed in patients with associated vitamin D deficiency. Other features like nephrocalcinosis (Fig 4), renal calculi (Fig 5) and pancreatic calcification (Fig 6) may be observed. Demographic clinical, radiological and biochemical profile of Indian patients are given in table – 1, 2 & 3 (2, 8, and 11).

The commonest abnormalities are hypercalcemia , phosphaturia and an elevated serum alkaline phosphatase level in the presence of increased serum parathyroid hormone levels. It is very important to correct the serum calcium level for the concomitantly measured albumin level. Without correction, the hypercalcemia may be missed in a hypoalbuminemic patient. Phosphaturia is assessed by calculating the TmP (tubular maximum for phosphate)/GFR (Glomerular Filtration Rate) using the Bijvoet nomogram (Fig 7). This is the proper method to assess phosphaturia rather than depend on an absolute range of urinary phosphate levels (12). Very high levels of parathyroid hormone associated with a palpable neck swelling traditionally favoured a diagnosis of parathyroid carcinoma. However in the Indian scenario this is not necessarily true, many palpable lesions are in fact benign.

Bone disease is severe in subjects with associated vitamin D deficiency (11,13). Postoperatively, vitamin D deficient subjects have been found to have more severe hypocalcemia when compared to patients with adequate vitamin D levels (11). In patients who are younger than 40 years of age a work up for Multiple Endocrine Neoplasia MEN 1/ MEN2A is indicated. It includes biochemical screening for prolactinomas (serum prolactin levels) in MEN-1 and pheochromocytomas (urinary and blood metanephrines and normetanephrines) and medullary carcinoma of thyroid (serum calcitonin) in MEN-2A.

Bone mineral density (BMD)

If bone mineral density is considered, the distal forearm would be the site at greatest risk for fracture and the lumbar spine would be the site for the smallest risk. The reason for this is that in mild primary hyperparathyroidism, reduction in cortical bone is frequent and the architecture of cancellous bone is well preserved. However, there is a paucity of data from India in connection with fracture risk, but BMD has been described to increase at all three sites (forearm, spine and hip) after successful surgery for primary hyperparathyroidism (3).

Pathology

The etiology of primary hyperparathyroidism is a parathyroid adenoma (Fig 8) in the vast majority of cases. Most patients harbour a single adenoma (14). The mean weight of the adenoma has been reported to be higher than that reported for patients in western literature. The weight of the parathyroid gland usually ranges from 1.2 gm to 15 gm in primary hyperparathyroidism. Four gland hyperplasia (Fig 9) is suspected in

hyperparathyroidism associated with MEN. The prevalence of parathyroid carcinoma associated with primary hyperparathyroidism is about 2-3 percent in the Indian population. Parathyroid carcinoma (Fig 10) is usually characterized by the presence of gross capsular and vascular invasion, cellular and nuclear pleomorphism and a high mitotic index with or without lymph node metastasis (2).

Brown tumours involving the skeleton observed in primary hyperparathyroidism are composed of multiple giant osteoclasts (giant cells) mixed with stromal cells and matrix. There is a familial form of hyperparathyroidism associated with jaw tumours in which the histology of the jaw tumor shows an ossifying fibroma. Severe bone disease is characterized by cystic lesions with accompanying fibrous tissue known as osteitis fibrosa cystica (Fig 11). Western literature describes this condition as pathognomic of renal bone disease, however in India, a fair number of subjects with hyperparathyroidism have the same problem.

Preoperative Localization

Bilateral neck exploration with identification of all parathyroid glands is considered by many to be the gold standard achieving a high success rate. Since a single adenoma is the defining cause in 80 to 90 percent of patients with sporadic hyperparathyroidism, its preoperative localization to one side could present an unnecessary contralateral exploration. The imaging techniques for pre operative localization include ultrasound, ^{99m}Tc –labeled sestamibi scan, computerized tomography and magnetic resonance imaging.

In the presence of hypercalcemia and elevated parathyroid hormone levels, ^{99m}Tc sestamibi scan is preferably done to locate the adenoma. If the ^{99m}Tc sestamibi scan is negative (as with multiple adenomas and hyperplasia) per operative localization by an experienced surgeon is advised. An ultrasonogram of the neck is done in difficult cases for localization of adenomas.

Sestamibi scan:

A ^{99m}Tc –labeled sestamibi scan (Fig 12) has been quoted as the most sensitive study for single adenomas (60 to 90 percent) and up to 60 percent for multiglandular disease. The specificity is 98-99 percent for single glandular disease and 100 percent for multiglandular disease (15). It is also more specific for ectopic glands (especially glands in the mediastinum).

Ultrasound:

High resolution ultrasound has emerged in recent years to be an alternative tool which is non invasive, less expensive and less time consuming for pre operative localization (16). The sensitivity and specificity are about 60 -80 percent and 95 percent for single glandular disease respectively. The false positive rate is 8-12 percent in western studies. However it may be dimmer in the Indian population due to a high prevalence of vitamin D deficiency. The sensitivity is lower in multi glandular disease (about 30 percent).

CT and MRI scanning:

They are more effective in detecting ectopic parathyroids in the anterior mediastinum and the tracheoesophageal groove.

Indications for the surgical management of hyperparathyroidism.

All symptomatic hyperparathyroidism (which includes most Indian patients) should be treated surgically. The indications for the surgical removal (17) are given in Table 4.

Surgical treatment

Exploration and removal of a parathyroid adenoma (Fig 13) by an experienced surgeon cures the condition. Minimally invasive parathyroid surgery has been developed recently to take full advantage of advances in localization and testing. As mentioned above, ^{99m}Techetium-labeled sestamibi plays an important role in the localization of tumours. The intra operative measurement of intact parathyroid hormone has being used in some centers to confirm the removal of diseased parathyroid tissue. The excision of a mediastinal parathyroid adenoma by a thoracoscopic approach has been described more recently to be a less invasive, more effective and a reasonably safe procedure (18).

Medical treatment

The principles for the management of primary hyperparathyroidism are similar to the treatment of hypercalcemia (19). The patients have to be well hydrated (especially in summer months). Diuretics like thiazides should be avoided as they can decrease calcium excretion and worsen hypercalcemia. The acute treatment of hypercalcemia includes hydration with intravenous saline and frusemide. The calcimimetic agent cinacalcet has

been found useful in treating mild hyperparathyroidism medically (20) but is very expensive and needs to be imported for use. Bisphosphonates such as alendronate (70 mg once a week) and parenteral zoledronate (4 mg intravenously) are effective for bone protection and hypercalcemia (21).

Conclusions

Indian patients with primary hyperparathyroidism have profound symptomatic bone disease. Asymptomatic hyperparathyroidism is a less common entity in the Indian population. The 99m Tc-sestamibi scanning is major imaging modality used for the preoperative localization of parathyroid adenomas. Most patients require surgery and excision by an experienced surgeon cures the condition in most cases. Associated vitamin D deficiency makes Indian patients more prone for hungry bone disease in the postoperative phase.

References:

1. Bilezikian JP. The Parathyroids – Basic and Clinical Concepts. Second Edition. 2001;663-670.
2. Bhansali A, Masoodi SR, Reddy, KSS, Behera A, et al. Primary hyperparathyroidism in north India: a description of 52 cases. Ann Saudi Med. 2005;25(1):29-35.
3. Paul TV, Thomas N, Seshadri MS, Oommen R, et al. Prevalence of Osteoporosis in ambulatory postmenopausal women from a semiurban region in southern India: Relationship to calcium nutrition and vitamin D status. Endocr Pract. 2008;14:665-671.
4. Agarwal G, Mishra SK, Kar DK, Singh AK, et al. Recovery pattern of patients with osteitis fibrosa cystica in primary hyperparathyroidism after successful parathyroidectomy. Surgery. 2002;132(6):1075-1085.
5. Das PP, Sharan P, Grover S, Behera A. Parathyroid adenoma presenting as bipolar affective disorder. Psychosomatics. 2007;48(6):532-533.
6. Goyal A, Chumber S, Tandon N, Lal R, Srivastava A, et al. Neuropsychiatric manifestations in patients of primary hyperparathyroidism and outcome following surgery. Indian J Med Sci. 2001;55(12):677-686.
7. Jebasingh F, Jacob JJ, Shah A, Paul TV, et al. Bilateral maxillary brown tumours as the first presentation of primary hyperparathyroidism. Oral Maxillofac Surg. 2008;12(2):97-100
8. Jacob JJ, John M, Thomas N, Selvan B, et al. Does hyperparathyroidism cause pancreatitis? A South India experience and a review of published work. ANZJ. Surg. 2006;76:740-744.
9. Bhadada SK, Udawat HP, Bhansali A, Rana SS, et al. Chronic pancreatitis in primary hyperparathyroidism: Comparison with alcoholic and idiopathic chronic pancreatitis. J Gastroenterol Hepatol. 2008 Jun;23(6):959-64.
10. Finny P, Jacob JJ, Thomas N. Primary hyperparathyroidism presenting as redness of eyes. Eur J Intern Med. 2007 Dec;18(8):608.

11. Priya G, Jyotsna, VP, Gupta N, Chumber S, et al. Clinical and laboratory profile of primary hyperparathyroidism in India. *Postgrad Med J.* 2008;84:34-39.
12. Walton RJ, Bijvoet OL. Nomogram for derivation of renal threshold phosphate concentration. *Lancet.* 1975;2(7929):309-10.
13. Harinarayan CV, Gupta N, Kochupillai N. Vitamin D status in primary hyperparathyroidism in India. *Clin Endocrinol (Oxf).* 1995;43(3):351-8.
14. Kapur MM, Agarwal MS, Gupta A, Misra MC, et al. Clinical & biochemical features of primary hyperparathyroidism. *Indian J Med Res.* 1985;81:607-612.
15. Gretchen P, Purcell, Frederick M, Dirbas, et al. Parathyroid Localization with high-resolution ultrasound and Technetium Tc 99m Sestamibi. *Arch Surg.* 1999;134:824-830.
16. Ammori BJ, Madan M, Gopichandran TD, Price JJ, et al. Ultrasound-guided unilateral neck exploration for sporadic primary hyperparathyroidism: is it worthwhile?. *Ann R Coll Surg Engl.* 1998 November; 80(6): 433–437.
17. NIH conference. Diagnosis and management of asymptomatic primary hyperparathyroidism: Consensus development conference statement. *Ann Intern Med.* 1991;114:593-597.
18. Kumar A, Kumar S, Aggarwal S, Tandon N, et al. Thoracoscopy: the preferred method for excision of mediastinal parathyroids. *Surg Laparosc Endosc Percutan Tech.* 2002;12(4):295-300.
19. Bilezikian JP. Management of acute Hypercalcemia. *N Engl J Med.* 1992;326:1196-1203.
20. Sajid-Crockett S, Singer FR, Hershman JM. Cinacalcet for the treatment of primary hyperparathyroidism. *Metabolism.* 2008;57(4):517-21.
21. Phitayakorn R, McHenry CR. Hyperparathyroid crisis: use of bisphosphonates as a bridge to parathyroidectomy. *J Am Coll Surg.* 2008;206(3):1106-15.

Table 1 – Demographic profile of Indian patients

Variable	Mean (SD)	Range
Age	37 (15.0)	12-72
Male / female ratio	1:3	
Duration of symptoms (months)	41(30)	1-256
Body mass index (kg/m ²)	21	13-32

Table-2 – Clinical and radiological profile of Indian patients:

Clinical / radiological manifestation	Percentage (%)
Bone pain	67-79
Proximal muscle weakness	56-77
Anorexia	12-44
Emotional lability	10-33
Palpable neck mass	11-31
Pancreatitis	12-13
Subperiosteal resorption	72-81
Brown tumors	59-86
Urinary / renal calculi	24-60
Fractures	41-48
Looser's zones	12-20
Nephrocalcinosis	13-18
Pancreatic calcification	3-10
Osteitis fibrosa cystica	26-58

Table 3 – Biochemical parameters for Indian patients with primary hyperparathyroidism

Biochemical parameter	Mean (SD)	Range
Corrected serum calcium (mg/dl)	12.52 (1.60)	9.6-17
Serum Phosphorus (mg/dl)	2.58 (0.56)	1.6-4.1
Serum PTH (ng/L)	662 (446)	88-1580
Serum alkaline phosphatase (IU/L)	320 ± 296	22-1578
Serum Creatinine (mg/dl)	1.20 (0.76)	0.5-4.7

Table 4 - The indications for the surgical removal

Evidence of any end organ complication of primary hyperparathyroidism, such as overt bone disease or stone disease.
Serum calcium concentration > 1 mg/dl above the upper limit of normal
An episode of Acute primary hyperparathyroidism.
Hypercalciuria exceeding 400 mg/day.
Evidence of reduced cortical bone mass at distal radius measured by bone densitometry (>2 SD below age and sex matched controls).
Age less than 50 years

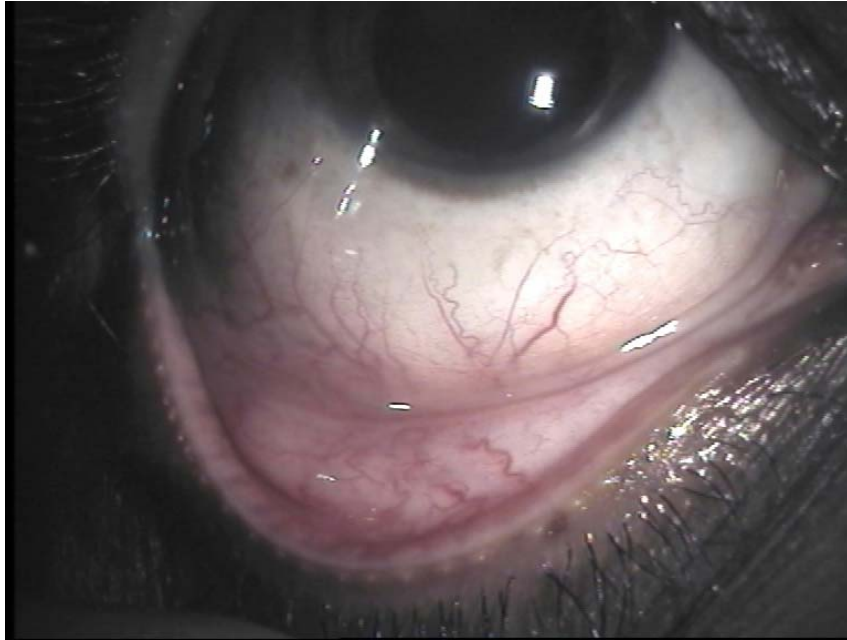


Figure 1 Red eye secondary to Hypercalcemia of hyperparathyroidism

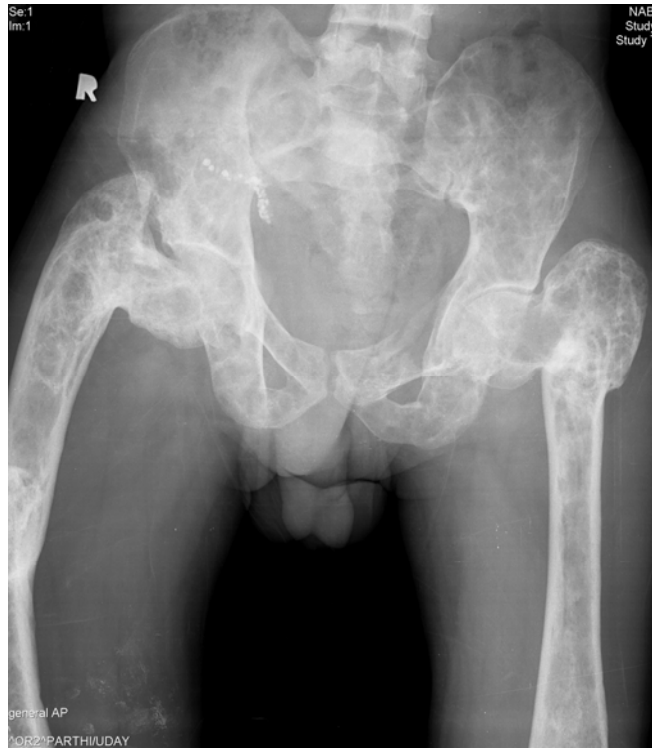

Figure 2 Osteitis fibrosa cystica of the pelvis and femur

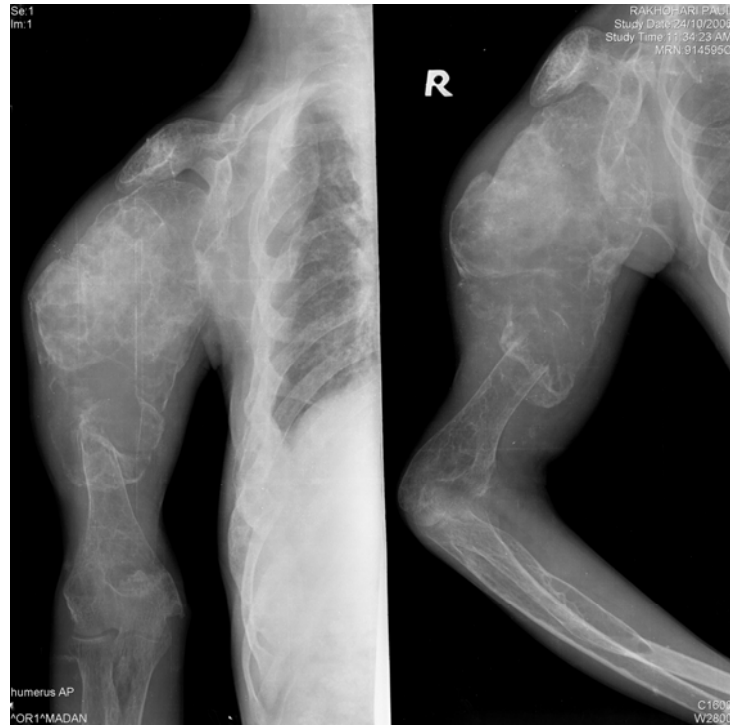


Figure 3 Osteitis fibrosa cystica of the humerus

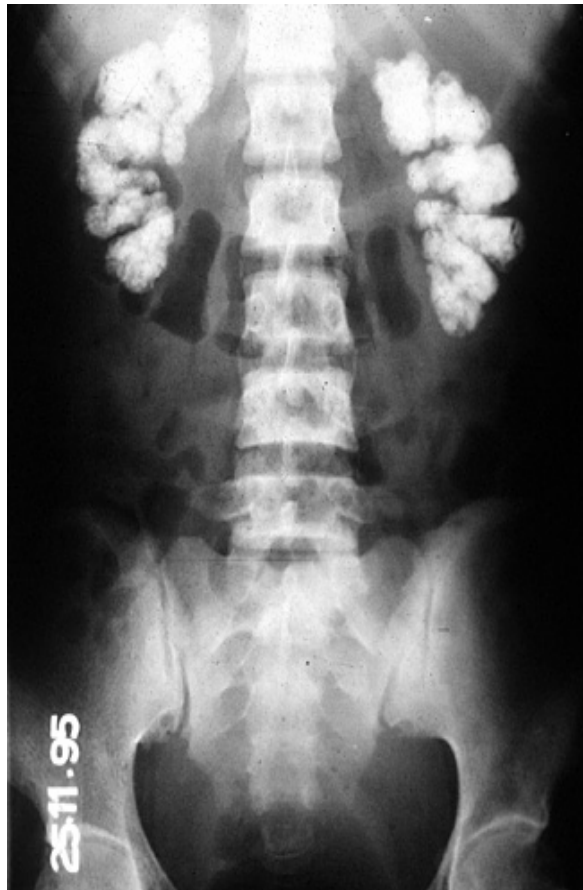

Figure 4 Nephrocalcinosis

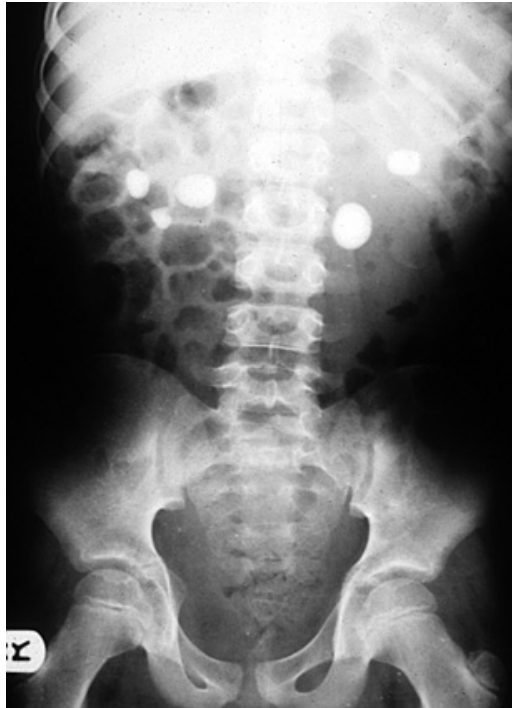

Figure 5 Bilateral renal calculi

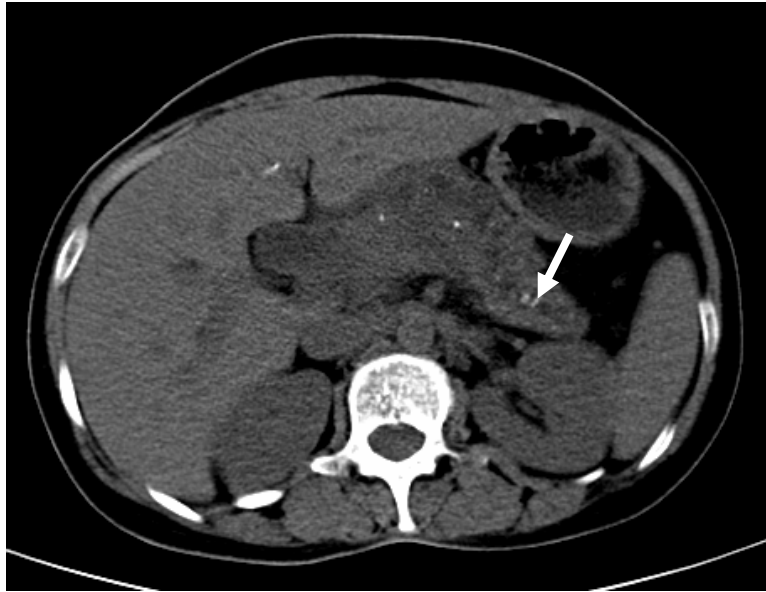


Figure 6 Computed tomography scan of the abdomen showing a bulky pancreas with dilated main pancreatic duct, intraparenchymal calcification and intraductal calculi (arrow).

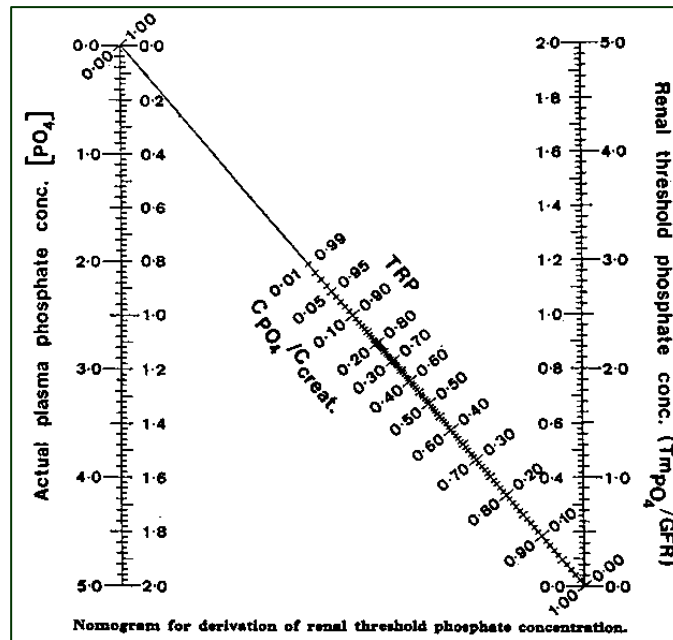


Figure 7 Bijvoet nomogram to calculate tubular maximum for phosphate.

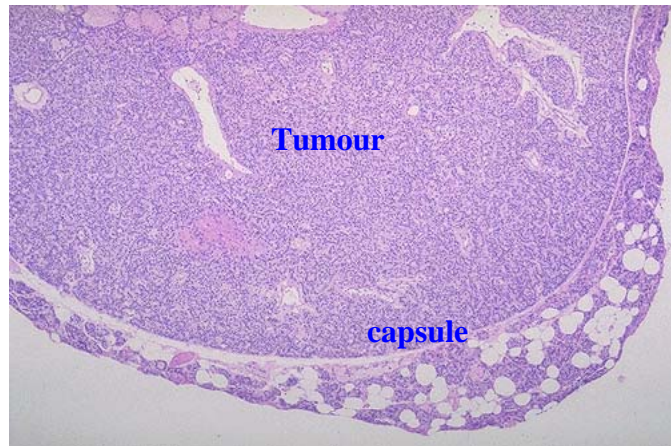


Figure 8 x50 magnification showing a parathyroid adenoma with a rim of the capsule

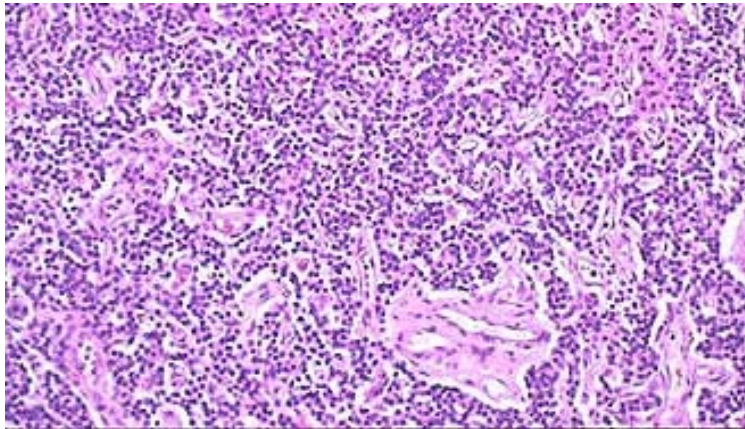


Figure 9 x100 magnification of parathyroid hyperplasia

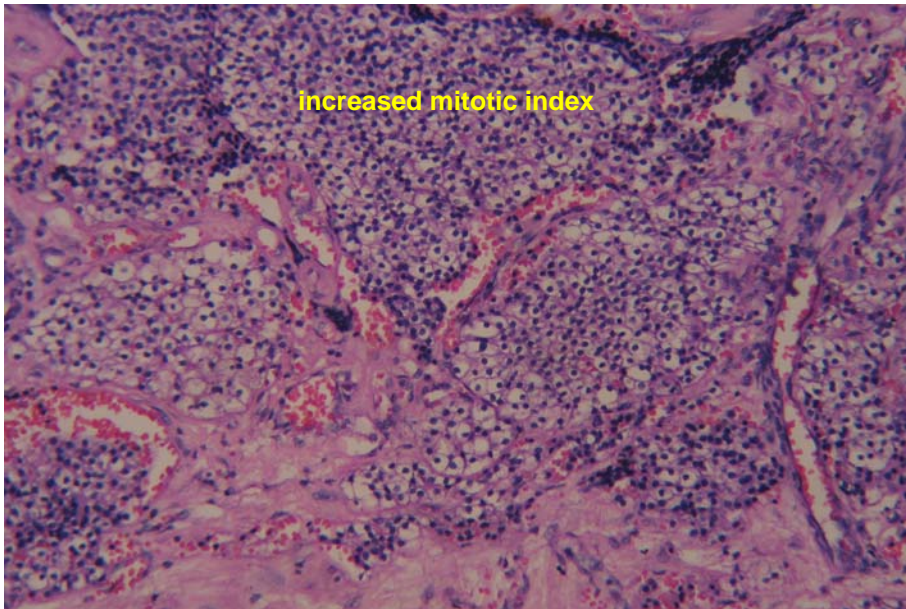


Figure 10 x200 magnification of parathyroid carcinoma showing an increased mitotic index and vascular invasion

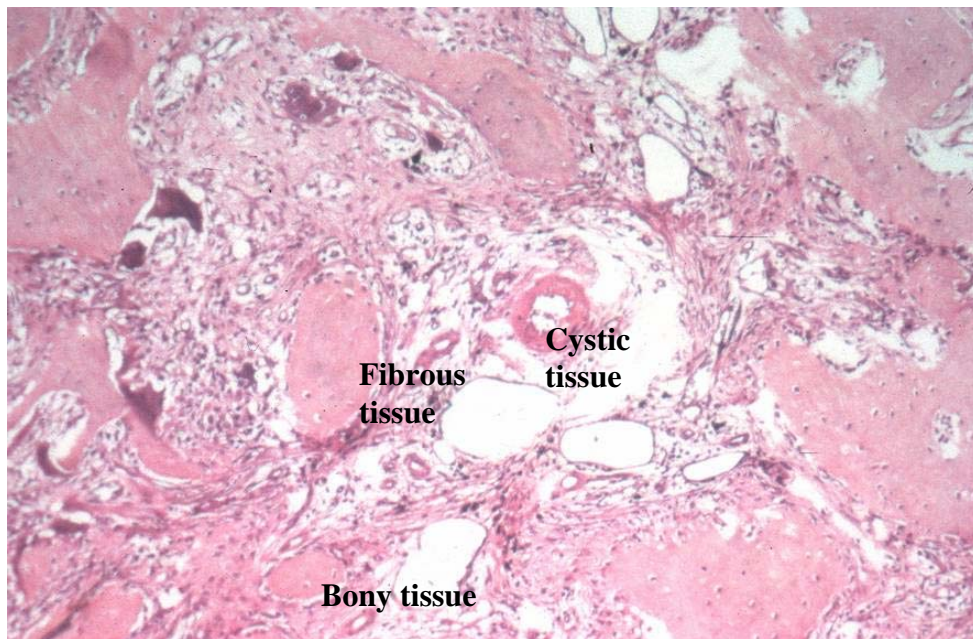


Figure 11 x 100 magnification of Osteitis fibrosa cystica

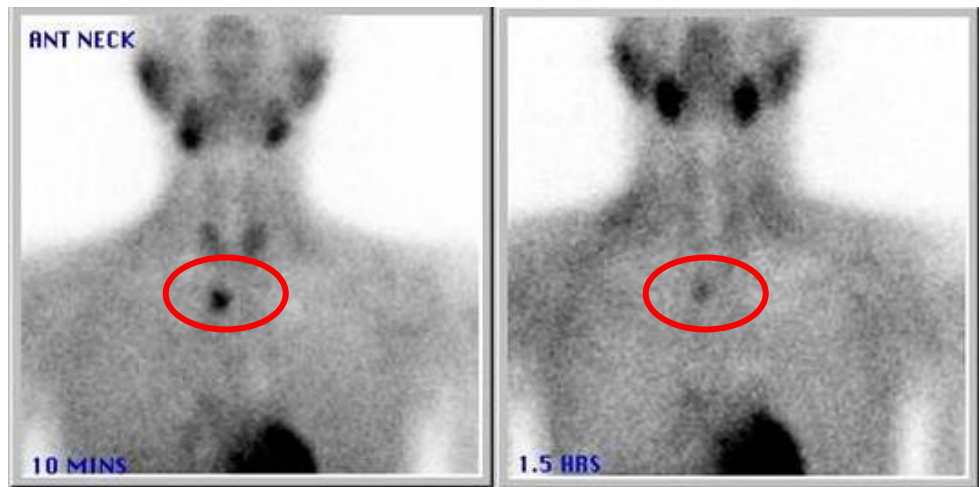


Figure 12 ^{99m}Tc sestamibi scan showing an ectopic parathyroid adenoma

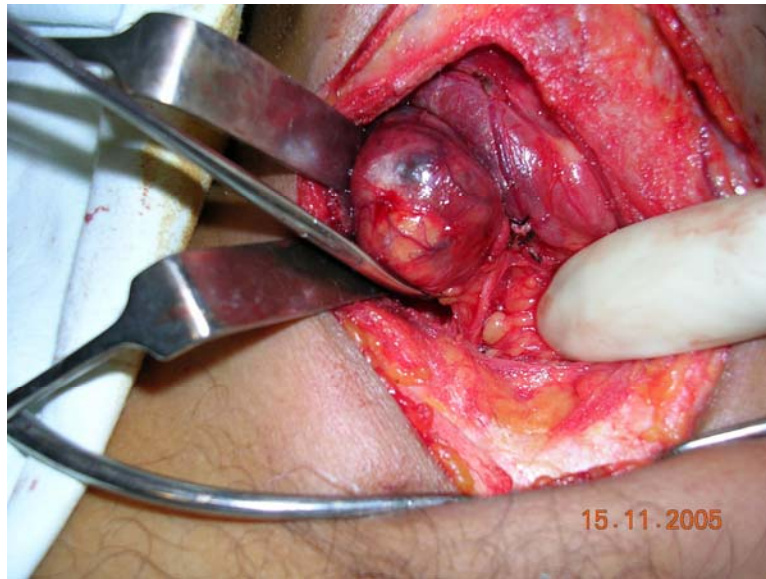


Figure 13 Surgery of neck exposing a parathyroid adenoma