

A Young Man with Bilateral Testicular Pain and Swelling

Roushon Ara Akter*, Noor Al Busaidi, Hilal Al Musalhi and Simon Rajaratnam

National Diabetes and Endocrine Centre, Royal Hospital, Muscat, Oman

ARTICLE INFO

Article history:

Received: 2 February 2016

Accepted: 21 April 2016

Online:

DOI 10.5001/omj.2016.93

A 17-year-old male diagnosed with congenital adrenal hyperplasia (CAH) at the age of six months presented to the endocrine clinic with pain and swelling in both testes. When he was seven years old he developed signs of precocious puberty and was treated with triptorelin 3.75 mg (intramuscular) once a month between 2007 and 2011. He was asked to continue long-term treatment with hydrocortisone (three times daily) 10/5/5 mg and fludrocortisone 100 mg (once daily). However, he was not regular with his medication.

Except for morbid obesity (body mass index = 51 kg/m²), his systemic examination was normal. Both testes were swollen and tender on palpation. Images of the ultrasound and Doppler of the left testes are shown [Figure 1 and 2].

Questions

1. What do the features on the ultrasound and doppler suggest?
 - a. Testicular adrenal rest tumors (TART)
 - b. Malignant Leydig cell tumor
 - c. Testicular abscess
 - d. Varicocele
2. His 17-OH Progesterone level was 282.5 nmol/L. What could be the cause?
 - a. Irregular compliance with medication
 - b. Taking a higher dose of medication
 - c. Stopped taking medication
 - d. Associated with other illness
3. What is the best management option?
 - a. Intensifying glucocorticoid therapy
 - b. Testes sparing surgery
 - c. Radiotherapy
 - d. Chemotherapy

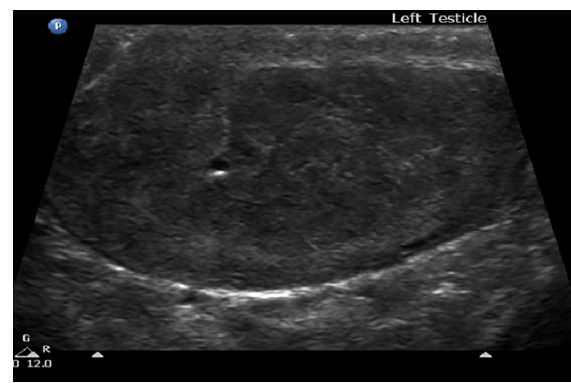

Figure 1: Ultrasound of the left testicle showing hyperechoic areas.




Figure 2: Doppler ultrasound of the left testicle showing increased vascularity.

CME CREDIT

You may earn CME credits by reading the quiz and answering the questions online. Answers for the quiz can be found online (www.omjournal.org). CME credits are awarded by Oman Medical Specialty Board by the Continued Professional Development Department.