

NEXT-GENERATION SEQUENCING-BASED GENETIC TESTING FOR FAMILIAL PARTIAL LIPODYSTROPHY

Hesarghatta Shyamasunder Asha, MBBS, MD, DNB (Endo);*

Aaron Chapla, MSc; Shrinath Shetty, MBBS, MD;*

Nihal Thomas, MBBS, MD, MNAMS, DNB (Endo), FRACP (Endo), FRCP (Edin), FRCP (Glasg)

ABSTRACT

Objective: Familial partial lipodystrophy (FPL) of the Dunnigan type (FPLD) is an autosomal dominant condition characterized by fat loss in the limbs and trunk, fat accumulation in the head and neck, and early onset diabetes mellitus. Here we describe the establishment and utilization of next-generation sequencing (NGS)-based genetic testing for FPLD.

Methods: We describe NGS-based mutational analysis of the lamin A/C (*LMNA*) gene, followed by confirmation through Sanger sequencing.

Results: We report a patient and her mother with accumulation of fat in the neck and face and loss of fat in the limbs and trunk typical of FPLD2, with young onset diabetes mellitus without ketoacidosis. Both subjects had elevated homeostasis model assessment estimated insulin resistance (HOMA-IR) values and serum triglyceride levels, indicating insulin resistance. Dual energy X-ray absorptiometry confirmed typical fat redistribution. NGS-based mutational analysis of the *LMNA* gene in these patients revealed a hot spot missense mutation (c.1444C>T, p.Arg482Trp) that was further confirmed by Sanger sequencing.

Conclusion: A high index of clinical suspicion is essential to make an accurate clinical diagnosis in subjects with diabetes at an early age. FPLD should be considered

in the differential diagnosis of monogenic diabetes with lipodystrophy. Ion torrent NGS offers flexibility and a multiplexing option that provides a robust and inexpensive platform for screening single-gene disorders. (AACE Clinical Case Rep. 2015;1:e00-e00)

Abbreviations:

FPL = familial partial lipodystrophy; **FPLD** = familial partial lipodystrophy of the Dunnigan type; **NGS** = next-generation sequencing

INTRODUCTION

Lipodystrophies are a group of clinically heterogeneous disorders characterized by abnormal adipose tissue distribution (1). Familial partial lipodystrophy (FPL) is a rare autosomal dominant condition, caused by missense mutations in *LMNA* gene encoding lamin A/C, resulting in accumulation of fat in the neck and face and atrophy of subcutaneous adipose tissue in the limbs and trunk (2) variable degrees of resistance to insulin action, together with a hyperlipidaemic state, may occur and simulate the metabolic features commonly associated with predisposition to atherosclerotic disease. The PLD locus has been mapped to chromosome 1q with no evidence of genetic heterogeneity. We, and others, have refined the location to a 5.3-cM interval between markers D1S305 and D1S1600 (refs 5, 6. FPL of the Dunnigan type 2 (FPLD2) is associated with a variety of metabolic disorders including dyslipidemia, insulin resistance, diabetes mellitus, and hepatic steatosis (3). We report the clinical features and mutational analysis of the *LMNA* gene in a Southern Indian patient and her mother who also had diabetes.

CASE REPORT

A 23-year-old female had been diagnosed with diabetes mellitus at the age of 16 when she presented with polyuria and skin lesions affecting her elbows. Her plasma glucose

*These authors contributed equally to this study.

Running title: NGS-based genetic testing for FPL, AACE Clinical Case Rep. 2015;1(No. 1)

Submitted for publication July 25, 2014

Accepted for publication August 25, 2014

From the Department of Endocrinology, Diabetes and Metabolism, Christian Medical College, Vellore, 632004, India.

Address correspondence to: Dr. Nihal Thomas, Professor and Head, Department of Endocrinology, Diabetes and Metabolism; Christian Medical College, Ida Scudder Road, Vellore, 632004, India.

E-mail: nihal_thomas@cmcvellore.ac.in

DOI:10.4158/EP14346.CR

To purchase reprints of this article, please visit: www.aace.com/reprints.

Copyright © 2015 AACE.

at diagnosis was 500 mg/dL and serum triglyceride levels were elevated with no history of ketoacidosis, abdominal pain, or steatorrhea. Insulin therapy was introduced from the time of diagnosis with suboptimal glycemic control. The skin lesions over the elbows resolved with treatment (probable eruptive xanthomas). Her menarche began at age 13, and she had regular menstrual cycles. Her height, weight, and body mass index were 158 cm, 44 kg, and 17.6 kg/m², respectively. She had a Cushingoid rounded appearance of the face without facial plethora. She also had grade 2 acanthosis nigricans over the neck, prominent muscle contours with minimal fat in the limbs, phlebomegaly, hepatomegaly, and vulval hypertrophy, suggestive of lipodystrophy. The age of onset of fat loss could not be determined. She had mild hirsutism (a modified Ferriman Galleway score of 11), but no clitoromegaly. She did not have cuticular atrophy, striae, ecchymoses, or hyperpigmentation of skin.

Her mother had been diagnosed with diabetes mellitus at age 30 and had been on insulin. Her menstrual cycles were regular. She had similar features of lipodystrophy with a Cushingoid rounded appearance of the face without plethora, phlebomegaly, muscular habitus, hepatomegaly, or vulval hypertrophy. She did not have hirsutism, clitoromegaly, or skin lesions (Fig. 1).

The proband's sister had a rounded face but normal glucose levels. The maternal uncle of the index case also had a rounded face and was diagnosed with diabetes at age 34. The maternal grandfather had diabetes, but further details were not available (Fig. 1).

The patient and her mother had elevated stimulated C-peptide levels (3.67 and 3.6 ng/mL, respectively) and homeostasis model assessment estimated insulin resistance

(HOMA-IR) values of 3.11 and 23.33 units, respectively (reference range, 1.0 to 2.6) suggestive of insulin resistance (4). The patient had hypertriglyceridemia (1,070 mg/dL), but her mother had normal serum triglycerides (118 mg/dL) on fenofibrate. Abdomen ultrasounds showed hepatic steatosis in both subjects. Dual energy X-ray absorptiometry in the subject and her mother demonstrated increased fat in the head and neck with reduced fat in the trunk and limbs confirming FPLD (Fig. 2) (5,6) Dunnigan variety, is an autosomal dominant disorder caused due to missense mutations in the lamin A/C (LMNA). The daughter's total body fat percentage was much lower than the third percentile for Indian girls aged 17 years; no age-matched normative value is available for the Indian population (7).

Diabetes mellitus in the proband was managed with a basal-bolus insulin regimen comprising insulin aspart and glargine with metformin. Hypertriglyceridemia and hypercholesterolemia were treated with a combination of atorvastatin and fenofibrate. Her mother's diabetes was managed with a basal-bolus insulin regimen of regular and neutral protamine Hagedorn insulin with Metformin, and triglycerides were maintained in the normal range with fenofibrate.

With a clinical suspicion of FPLD, amplicon sequencing of the *LMNA* gene was performed using next-generation sequencing (NGS). The coding region of the 12 exons with additional >50 bp to accommodate areas upstream and downstream of each exon to capture the intron/exon boundaries and the 5' and 3' regions of the *LMNA* gene were amplified with 9 pairs of novel primers designed using Primer3 software. Following polymerase chain reaction-based target enrichment, library preparation and NGS was performed on the Ion torrent personal genome

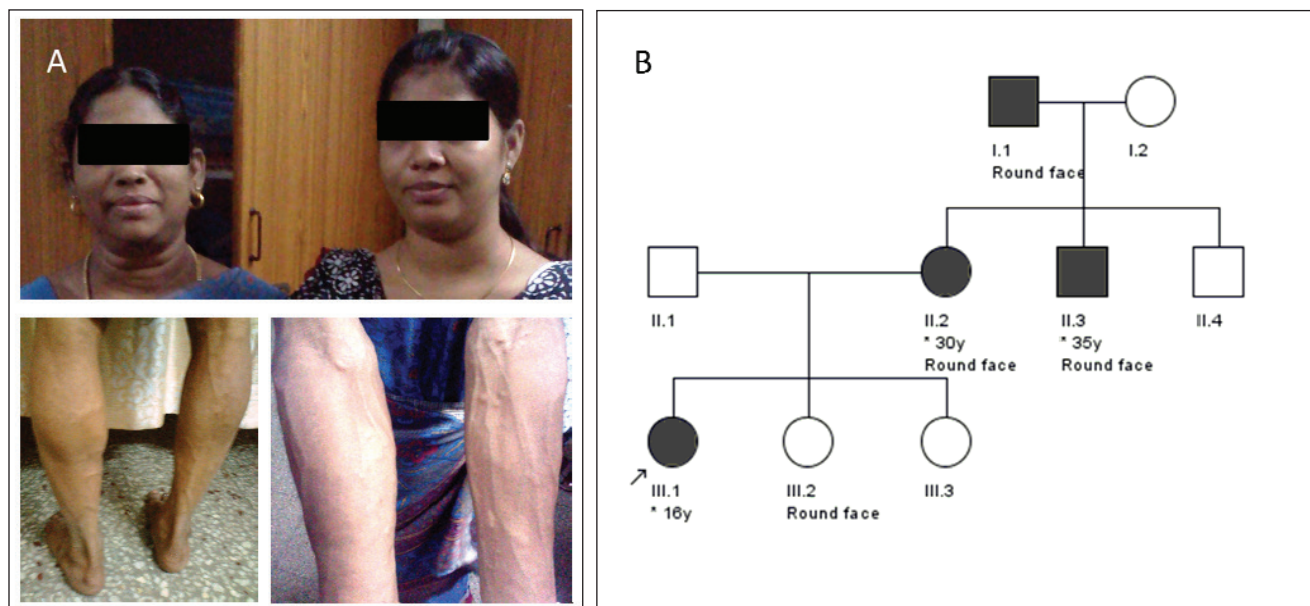


Fig. 1. (A) Clinical photographs of the subject and her mother showing Cushingoid faces and lipoatrophy in the limbs with phlebomegaly, (B) Pedigree chart of the affected family.

Fig. 3. Next-generation sequencing reads aligned with reference sequence hg 19; the identified mutation was further conformed by Sanger sequencing.

with lipodystrophy. In the present study, ion torrent NGS with multiplexing capability that uses an inexpensive bar-coding system was utilized, and the identified mutation was further confirmed by Sanger sequencing. Once evaluated, these strategies could be utilized in clinical settings to provide confirmed genetic diagnoses, thereby guiding appropriate treatment, prognostication, genetic counseling, and early screening and treatment for first-degree relatives.

CONCLUSION

FPLD should be considered in the differential diagnosis of monogenic diabetes with lipodystrophy. A high index of clinical suspicion is essential to make an accurate clinical diagnosis in subjects with diabetes at an early age. Appropriate biochemical and genetic testing provides a clear understanding of the pathophysiology, enabling better treatment and outcomes. Ion torrent NGS offers flexibility with a multiplexing option that provides a robust and inexpensive platform for screening single-gene disorders.

DISCLOSURE

The authors have no multiplicity of interest to disclose.

ACKNOWLEDGMENT

We thank Mrs. Manika Varshney, Mrs. Papitha Sakthivel, Mrs. Deny Varghese, Mrs. Mercy Inbakumari, and Mrs. Banu for their contributions to various aspects of the study.

REFERENCES

1. **Garg A.** Acquired and inherited lipodystrophies. *N Engl J Med.* 2004;350:1220-1234.
2. **Shackleton S, Lloyd DJ, Jackson SN, et al.** LMNA, encoding lamin A/C, is mutated in partial lipodystrophy. *Nat Genet.* 2000;24:153-156.
3. **Garg A.** Lipodystrophies. *Am J Med.* 2000;108:143-152.
4. **Ascaso JF, Pardo S, Real JT, Lorente RI, Priego A, Carmena R.** Diagnosing insulin resistance by simple quantitative methods in subjects with normal glucose metabolism. *Diabetes Care.* 2003;26:3320-3325.
5. **Monteiro LZ, Foss-Freitas MC, Júnior Montenegro RM, Foss MC.** Body fat distribution in women with familial partial lipodystrophy caused by mutation in the lamin A/C gene. *Indian J Endocrinol Metab.* 2012;16:136-138.
6. **Vantyghem MC, Pigny P, Maurage CA, et al.** Patients with familial partial lipodystrophy of the Dunnigan type due to a LMNA R482W mutation show muscular and cardiac abnormalities. *J Clin Endocrinol Metab.* 2004;89:5337-5346.
7. **Khadgawat R, Marwaha RK, Tandon N, et al.** Percentage body fat in apparently healthy school children from northern India. *Indian Pediatr.* 2013;50:859-866.
8. **Vigouroux C, Magré J, Vantyghem MC, et al.** Lamin A/C gene: sex-determined expression of mutations in Dunnigan-type familial partial lipodystrophy and absence of coding mutations in congenital and acquired generalized lipoatrophy. *Diabetes.* 2000;49:1958-1962.
9. **Hegele RA.** Lessons from human mutations in PPARgamma. *Int J Obes (Lond).* 2005;29 Suppl 1:S31-35.
10. **Hegele RA, Cao H, Frankowski C, Mathews ST, Leff T.** PPARG F388L, a transactivation-deficient mutant, in familial partial lipodystrophy. *Diabetes.* 2002;51:3586-3590.
11. **Gandotra S, Le Dour C, Bottomley W, et al.** Perilipin deficiency and autosomal dominant partial lipodystrophy. *N Engl J Med.* 2011;364:740-748.
12. **Rubio-Cabezas O, Puri V, Murano I, et al.** Partial lipodystrophy and insulin resistant diabetes in a patient with a homozygous nonsense mutation in CIDEC. *EMBO Mol Med.* 2009;1:280-287.
13. **George S, Rochford JJ, Wolfrum C, et al.** A family with severe insulin resistance and diabetes due to a mutation in AKT2. *Science.* 2004;304:1325-1328.
14. **Garg A.** Gender differences in the prevalence of metabolic complications in familial partial lipodystrophy (Dunnigan variety). *J Clin Endocrinol Metab.* 2000;85:1776-1782.