

CASE REPORT

Pituitary tuberculoma with subsequent drug-resistant tuberculous lymphadenopathy: an uncommon presentation of a common disease

Geethu Antony,¹ Riddhi Dasgupta,² Geetha Chacko,¹ Nihal Thomas²

¹Christian Medical College and Hospital Vellore, Vellore, Tamil Nadu, India

²Department of Endocrinology, Diabetes and Metabolism, Christian Medical College, Vellore, Tamil Nadu, India

Correspondence to

Dr Riddhi Dasgupta,
riddhi_dg@rediffmail.com

Accepted 30 January 2017

SUMMARY

We report a case of pituitary tuberculosis which presented as a non-functioning pituitary macroadenoma, and subsequently developed multidrug-resistant tuberculous lymphadenopathy. Pituitary tuberculosis continues to be a rare presentation of tuberculosis, but incidence and prevalence are expected to grow with increasing numbers of multidrug-resistant tuberculosis. Isolated pituitary tuberculosis is rare. Tuberculosis should be considered in the differential diagnosis in evaluation of a sellar mass.

BACKGROUND

Tuberculosis of the pituitary is a very rare entity. It accounts for only 1% of intracranial tuberculomas.¹ It presents as a sellar mass with combined pituitary hormone deficiency and with optic nerve compression. Clinical and radiological diagnosis of tuberculosis as an aetiology of the sellar mass is difficult in most cases. The diagnosis is generally determined by histopathology which shows necrotising granulomatous inflammation. Acid-fast bacilli are rarely demonstrated in these lesions, which make treatment and follow-up difficult. Associated systemic involvement is not seen commonly. Here we discuss, a case of pituitary tuberculosis presenting as a non-functioning pituitary macroadenoma, who later developed multidrug-resistant tuberculosis of the lymph node.

CASE PRESENTATION

A 30-year-old woman presented to our endocrinology clinic with a history of intermittent holocranial headache and diminution of vision of the left eye for 2 months duration without any other neurological symptoms or history suggestive of systemic involvement. Her history and family history were unremarkable and no history of previous or recent contact with tuberculosis could be elicited. Her clinical examination was unremarkable except for mild pallor. Visual field assessment showed temporal haemianopia of the left eye with early temporal disc pallor.

INVESTIGATIONS

Biochemical evaluation of pituitary hormonal profile revealed a serum cortisol 08:00: 21 µg/dL (normal: 7–25 µg/dL), TSH 2.67 µIU/mL (normal: 0.4–4.5 µIU/mL), T4: 5.5 g/µdL (normal: 4.5–12.5 µg/dL), FTC –0.93 ng/dL (0.8–2 ng/dL), prolactin 21 ng/mL (normal: 5–25 ng/mL), FSH

3.6 mIU/mL (normal: –2.8–11.3 mIU/mL) and LH 1.5 mIU/mL, while other biochemical parameters were essentially normal except for a haemoglobin level of 10.2 gm%. Gadolinium-enhanced MRI of the pituitary showed a sellar mass of size 2.3×2×1.3 cm, with suprasellar extension and optic nerve compression. The lesion was isointense in T1 ([figure 1A](#)) with an enhancement in postgadolinium images suggestive of pituitary macroadenoma ([figure 1B](#)).

DIFFERENTIAL DIAGNOSIS

The differentials considered were:

- ▶ Non-functioning pituitary macroadenoma
- ▶ Craniopharyngioma
- ▶ Hypophysitis-lymphocytic
- ▶ Granulomatous inflammation of the pituitary
- ▶ Meningioma
- ▶ Hypothalamic astrocytoma/glioma
- ▶ Germinoma
- ▶ Chordoma
- ▶ Pituitary metastases
- ▶ Pituitary carcinoma.

TREATMENT

She subsequently underwent a transnasal transsphenoidal radical excision of the adenoma. Postoperative histopathology showed granulomatous inflammation with foci of caseating necrosis, suggestive of tuberculosis ([figure 2A, B](#)). However the Ziehl-Neelsen staining and culture for mycobacterium tubercule bacilli (MTB) were negative and no other systemic involvement of tuberculosis was found. Based on the clinical, radiological and histopathological findings, a probable diagnosis of tuberculosis was made. The patient was started on antituberculosis drug treatment and was advised a total duration of 18 months (3 months of intensive phase and 15 months of continuation phase) of therapy. Postoperatively, she developed biochemical evidence of hypocortisolism. (Serum cortisol at 08:00: 3.2 µg/dL (normal: 7–25 µg/dL), TSH 0.876 µIU/mL (normal: 0.5–4.5 µIU/mL) T4: 3.0 µg/dL (normal: 4.5–12.5 µg/dL), FTC –0.68 ng/dL (0.8–2 ng/dL)) without any other pituitary axes involvement and was started on supplementation with oral prednisolone (5 mg/day) and levothyroxine (50 µg/day). Her headache and visual problems gradually improved with treatment and she remained asymptomatic for the duration of treatment. The patient had been on regular follow-up with the physician in her native place during the 18 months of



CrossMark

To cite: Antony G, Dasgupta R, Chacko G, et al. *BMJ Case Rep* Published online: [please include Day Month Year] doi:10.1136/bcr-2016-218330

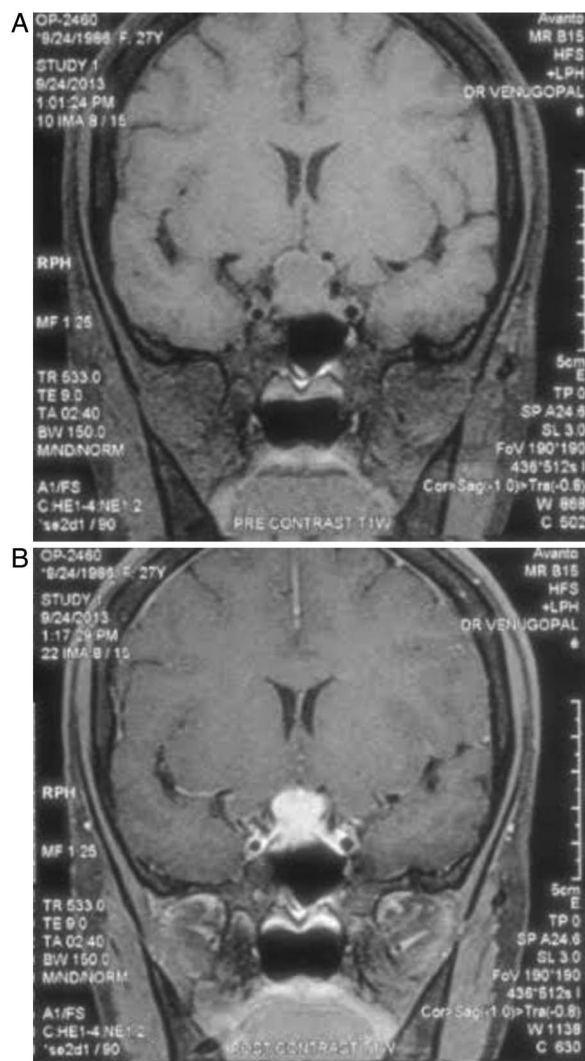


Figure 1 (A) T1-weighted coronal MRI image of brain showing an isointense mass in the pituitary region extending in to the suprasellar region. (B) Post contrast T1-weighted coronal image of brain showing contrast enhancement of the lesion. The normal pituitary is not seen separately.

antitubercular therapy and documentation of compliance with the antitubercular treatment was adequately maintained by the consulting physician.

OUTCOME AND FOLLOW-UP

After 2 years, she noticed multiple swellings in the neck with no associated systemic symptoms and was found to have significant bilateral cervical lymphadenopathy. Biopsy of the cervical lymph node revealed multiple confluent and discrete granulomas with Langerhans-type giant cells and large areas of caseous necrosis (figure 3). Though the stain for acid-fast bacilli and liquid culture by mycobacterium growth indicator tube (MGIT) were negative, the tuberculosis PCR by Genexpert was positive and showed resistance to rifampicin. After ruling out any underlying immunocompromised condition, the patient was started on second-line antituberculosis treatment with the intensive phase comprising kanamycin 500 mg intramuscular, cycloserine 750 mg, ethionamide 750 mg, pyrazinamide 1.25 gm, ethambutol 1000 mg, levofloxacin 750 mg and clofazimine 100 mg. A whole-body fluorodeoxyglucose positron-emission tomography (FDG-PET) CT undertaken to look for dissemination of the

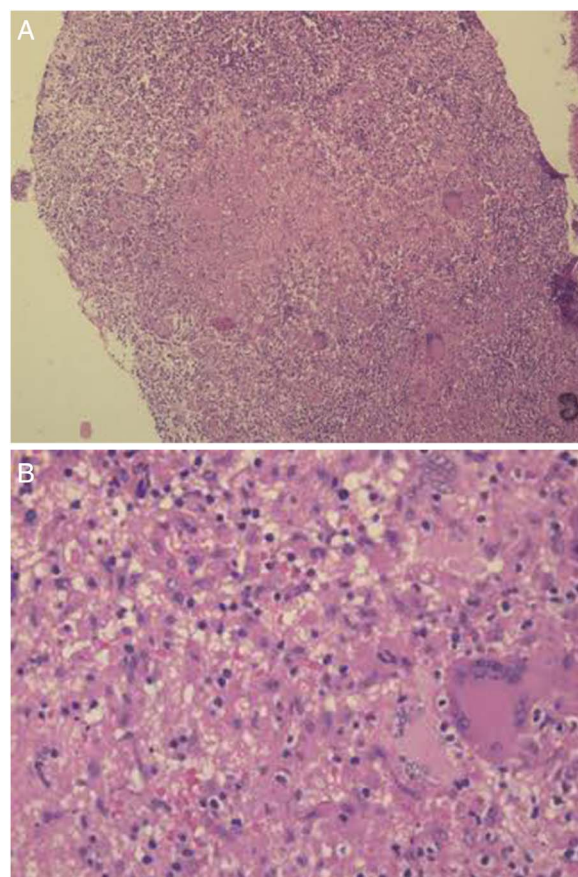


Figure 2 (A) Histopathology of the sellar mass showing caseating granulomatous inflammation. (B) High-power image of the same lesion showing multinucleate giant cell of langerhans cell type.

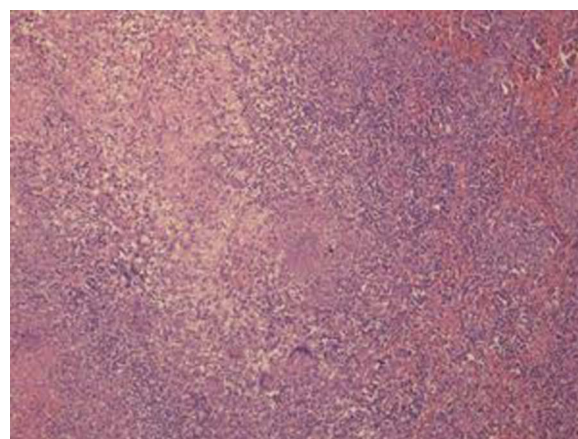


Figure 3 Histopathology of the cervical lymph node showing caseating granulomatous inflammation.

disease revealed significant cervical, axillary and periportal lymphadenopathy (figure 4). A repeat MRI pituitary was performed which showed complete resolution of the sellar mass with postoperative changes in the sella. She was continued on oral steroid and thyroxine supplementation with her biochemical parameters at 2 years follow-up revealing a T4: 7.01 µg/dL (normal: 4.5–12.5 µg/dL), FTC –1.02 ng/dL (0.8–2 ng/dL) and TSH: 1.67 µIU/mL (normal: 0.4–4.5 µIU/mL), with normal electrolytes.

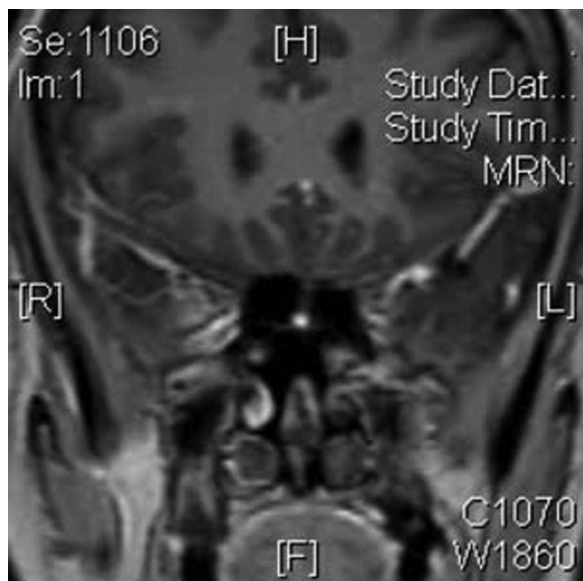


Figure 4 Follow-up MRI image—post contrast T1-weighted coronal image of the brain showing postoperative changes in sellar floor and thin rim of pituitary gland along the floor and normal pituitary stalk.

The patient is on regular follow-up with us and has completed 4 months of her treatment uneventfully with significant clinical reduction in the cervical lymphadenopathy. She is planned for a repeat PET imaging at the end of intensive phase to look for adequacy of response to treatment.

DISCUSSION

Central nervous system (CNS) tuberculosis accounts for <4% of all intracranial tumours.² Although tuberculosis has been described as a cause of granulomatous hypophysitis, tuberculosis of the pituitary is a very rare entity. The first case was reported from Britain by Coleman and Meredith in 1924, though most of the cases reported thereafter are from developing countries, mainly from Indian subcontinent.³ Only around 60 cases are reported so far in literature. Pituitary tuberculosis can present either as isolated CNS involvement or with concomitant or history of extracranial involvement. Sellar involvement can be either a haematogenous spread from the primary extracranial foci or contiguous spread from skull base. We have discussed a patient who presented with isolated pituitary involvement, who developed lymph nodal tuberculosis 2 years later on follow-up. In the largest series of pituitary tuberculosis described in literature by Sharma *et al*,⁴ five out of 18 patients had past or concomitant extracranial involvement. Three patients had history of pulmonary tuberculosis which was the most common association. Only one patient had associated lymph nodal tuberculosis, similar to our patient.

The most common symptoms reported are headache (91%) followed by visual problems (46%). Owing to the compression various hormone deficiencies can be seen mimicking non-functioning pituitary macroadenoma. According to literature, anterior pituitary hormone deficiencies are seen in around 60–80% of the patients.⁵ Hyperprolactinaemia due to stalk effect is seen in 20–25%.⁶ Posterior pituitary involvement and diabetes insipidus were reported in 11–28% in various case series.⁵ Systemic symptoms are usually absent. Clinical diagnosis of tuberculosis is extremely difficult in isolated pituitary involvement. In most of the cases, series diagnosis is made with histopathology or by associated extracranial involvement. Our

patient also presented with headache and visual symptoms. Preoperatively she did not have any hormone deficiency. Prolactin levels were normal.

Radiologically, pituitary tuberculosis is difficult to differentiate from pituitary macroadenomas and other inflammatory lesions. Pituitary stalk thickening and nodularity are seen commonly in tuberculosis, but is non-specific as it is seen in other inflammatory conditions like sarcoidosis, syphilis, idiopathic hypophysitis and malignancies. The lesions are seen isointense to hypointense in T1-weighted MR images and hyperintense in T2-weighted images and show intense enhancement with contrast. Hyperintense T1-weighted lesions are also described in literature due to thick protein content.⁷ Ring-enhancing lesions are also described with hypointense areas correspond to caseous necrosis. The differential diagnosis of tuberculosis should be kept in mind for non-functioning sellar masses particularly in those with stalk thickening. This is more relevant in developing countries where the prevalence of tuberculosis continues to be high.

The histopathological examination of our case revealed caseating granulomas with langerhans giant cells which is characteristic of tuberculosis. The caseating necrosis differentiates tuberculosis from other causes of granulomatous inflammation. The diagnosis requires confirmation by identification of acid-fast bacilli by Ziehl-Neelsen staining or culture or by PCR for detection of mycobacterial nucleic acid. Isolation of tubercle bacilli from the sellar lesion is extremely rare.⁸ In our patient the bacilli were not seen in the sellar lesion. However during follow-up she developed lymph nodal tuberculosis and multidrug-resistant tubercle bacilli was isolated by PCR method, which is sensitive and specific for diagnosis of tuberculosis. Though sellar tuberculoma with preceding or concomitant extracranial involvement has been reported, we presume that the presentation of drug-resistant tuberculous lymphadenopathy as a late manifestation of a primary sellar tuberculoma is unique.

Surgery is not usually indicated, except for obtaining biopsies to confirm diagnosis, as these lesions tend to resolve with appropriate antituberculous treatment (ATT) is mandatory in all patients even if the lesion is removed surgically.⁹ There is no consensus regarding the type of antitubercular regimen and duration of the treatment as the experience with tuberculomas of pituitary is limited. Our patient had completed 18 months of ATT and then within 6 months she developed drug-resistant tuberculous lymphadenopathy.

In conclusion, possibility of tuberculosis should be considered in evaluation of sellar mass, especially in developing countries. The definite diagnosis with histopathology is advisable, since the number of drug resistant tuberculosis is on rise, especially in immunocompromised patients.

Learning points

- ▶ Isolated pituitary tuberculosis is an extremely rare disease manifestation.
- ▶ It can mimic pituitary adenomas.
- ▶ Important differential for sellar mass.
- ▶ Histopathological diagnosis is advisable.
- ▶ Long-term follow-up is needed owing to large number of drug-resistant tuberculosis cases in India.

Contributors All authors have contributed equally to the manuscript. RDG performed data analysis, manuscript drafting and final revision. GA contributed to study design, data analysis, manuscript draft and final revision. GC performed data analysis and final revision. NT performed data analysis and final revision.

Competing interests None declared.

Patient consent Obtained.

Provenance and peer review Not commissioned; externally peer reviewed.

REFERENCES

- 1 Sunil K, Menon R, Goel N. Pituitary tuberculosis. *J Assoc Physicians of India* 2008;32:453–6.
- 2 Srisukh S, Tanpaibule T, Kiertiburanakul S, et al. Pituitary tuberculoma: a consideration in the differential diagnosis in a patient manifesting with pituitary apoplexy-like syndrome. *IDCases* 2016;5:63–6.
- 3 Letchworth TW. Tuberculoma of the pituitary body. *BMJ* 2011;1126–7.
- 4 Sharma MC, Arora R, Mahapatra AK, et al. Intracellular tuberculoma—an enigmatic pituitary infection: a series of 18 cases. *Clin Neurol Neurosurg* 2000;102:72–7.
- 5 Dalan R, Leow MK. Pituitary abscess: our experience with a case and a review of the literature. *Pituitary* 2011;3:299–306.
- 6 Furtado SV, Venkatesh PK, Ghosal N, et al. Isolated sellar tuberculoma presenting with panhypopituitarism: clinical, diagnostic considerations and literature review. *Neurol Sci* 2011;32:301–4.
- 7 Patankar T, Patkar D, Bunting T, et al. Imaging in pituitary tuberculosis. *Clin Imaging* 2000;24:89–92.
- 8 Petrossians P, Delvenne P, Flandroy P, et al. An unusual pituitary pathology. *J Clin Endocrinol Metabolism* 1998;83:3454–8.
- 9 Dutta P, Bhansali A, Singh P, et al. Suprasellar tubercular abscess presenting as panhypopituitarism: a common lesion in an uncommon site with a brief review of literature. *Pituitary* 2009;32:73–7.

Copyright 2017 BMJ Publishing Group. All rights reserved. For permission to reuse any of this content visit <http://group.bmj.com/group/rights-licensing/permissions>.
BMJ Case Report Fellows may re-use this article for personal use and teaching without any further permission.

Become a Fellow of BMJ Case Reports today and you can:

- Submit as many cases as you like
- Enjoy fast sympathetic peer review and rapid publication of accepted articles
- Access all the published articles
- Re-use any of the published material for personal use and teaching without further permission

For information on Institutional Fellowships contact consortiasales@bmjgroup.com

Visit casereports.bmj.com for more articles like this and to become a Fellow