

Three siblings with Woodhouse–Sakati syndrome in an Indian family

George Koshy^a, Sumita Danda^b, Nihal Thomas^a, Vikram Mathews^c and Vijay Viswanathan^d

Woodhouse–Sakati syndrome consists of alopecia, hypogonadism, diabetes mellitus, mild mental retardation, sensorineural deafness and ECG abnormalities. The proband described here has the above-mentioned features and presented with idiopathic thrombocytopenic purpura not reported before. Phenotypic variability is present in the three affected siblings. The two sisters have hypergonadotropic hypogonadism and the brother has hypogonadotropic hypogonadism. Camptodactyly of fourth and fifth fingers is seen in proband and her brother. We report for the first time three affected siblings of Woodhouse–Sakati syndrome in an Indian family. Clin Dystrophol 17:57–60 © 2008 Wolters Kluwer Health | Lippincott Williams & Wilkins.

Clinical Dystrophology 2008, 17:57–60

Keywords: India, thrombocytopenia, Woodhouse–Sakati

Departments of ^aEndocrinology, ^bClinical Genetics, ^cHaematology, Christian Medical College, Vellore and ^dM.V. Hospital for Diabetes (Pvt) Ltd., Chennai, India

Correspondence to Dr Sumita Danda, Clinical Genetics Unit, Christian Medical College, Vellore 632 004, India
Tel: + 91 0416 2282148/2283161;
fax: + 91 416 2232035/2232054/2232103;
e-mail: sdanda@cmcvellore.ac.in

Received 14 April 2007 Accepted 30 May 2007

Introduction

Woodhouse–Sakati syndrome is a rare genetic syndrome, first described by the two authors in two highly inbred Saudi Arabian families (Woodhouse and Sakati, 1983). We present a family from South India in which all three siblings have Woodhouse–Sakati syndrome. The proband presented with idiopathic thrombocytopenia not previously described in this syndrome.

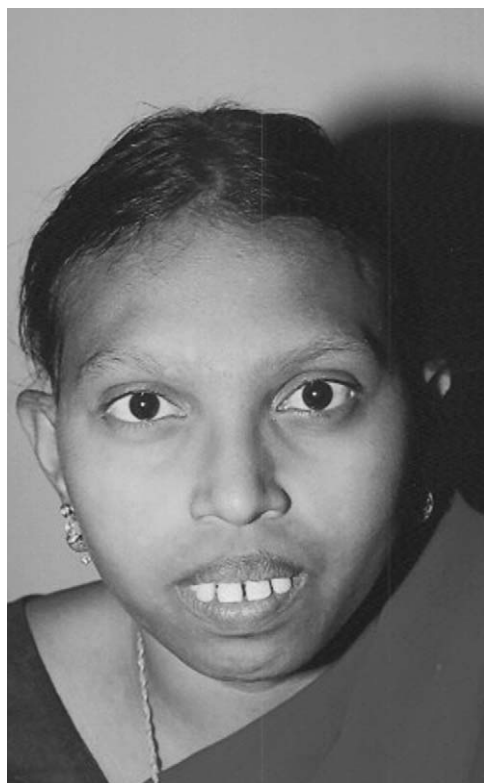Case reports

The proband was a 20-year-old girl who was referred to our hospital with a history of bleeding gums intermittently and hematuria in the past. She was diagnosed to have idiopathic thrombocytopenic purpura and was started on oral steroids. Before this she was diagnosed to have diabetes by a local practitioner and started on insulin and oral hypoglycemic agents. At the age of 15 years, she had menstrual bleeding for a day after which she had remained amenorrheic having failed to achieve withdrawal bleeding with hormonal preparations. She gave a history of progressive alopecia for the previous 3 years. Hearing loss was noticed over the last 3 months. She was born by vaginal delivery of a normal pregnancy. Her milestones were normal. Her performance at school was below average. She had dropped out of school in Class 8. On tracing four generations of the family history, it was found that the father's paternal grandmother and the mother's paternal grandmother were cousins; children of two brothers. Her mother's elder brother had a daughter – who had been pale and edematous and died of

severe diarrhea and dehydration at the age of 32 years. She too had alopecia and amenorrhea.

Physical examination of the proband revealed height of 156 cm, weight of 65 kg. The arm span was 168 cm, the upper/lower segment ratio was 0.79. She has a high-forehead, hypertelorism, telecanthus, a rounded face with prominent upper incisors, malocclusion, sparse scalp hair and eyebrows (Figs 1 and 2). She had a wide carrying angle with fixed flexion deformities of the fourth and fifth fingers of both hands. The hands appeared large (Fig. 3). She had underdeveloped secondary sex characters. A formal eye and hearing assessment revealed compound myopic astigmatism with high myopia, left divergent squint and left amblyopia with no features of diabetic retinopathy and bilateral moderate sensorineural hearing loss, respectively. The rest of the physical examination was normal. The investigations revealed platelets of 11 000/mm denoting thrombocytopenia, a high FSH of 29.9 mIU/ml (reference range 2.8–11.3 mIU/ml) (denoting hypergonadotropic hypogonadism). LH was 10.3 mIU/ml (reference range 1.1–11.6 follicular). The karyotype was normal. An ultrasound scan of the abdomen did not display ovaries or uterus. The bone marrow smear showed features of mildly hypercellular marrow with erythroid hyperplasia and increased megakaryocytes suggestive of peripheral platelet destruction, bone marrow trephine revealed mildly hypocellular marrow with adequate megakaryocytes. Both were in keeping with the diagnosis of idiopathic thrombocytopenic purpura. Blood sugars were indicative of diabetes mellitus and insulin antibodies were negative. ECG

Fig. 1



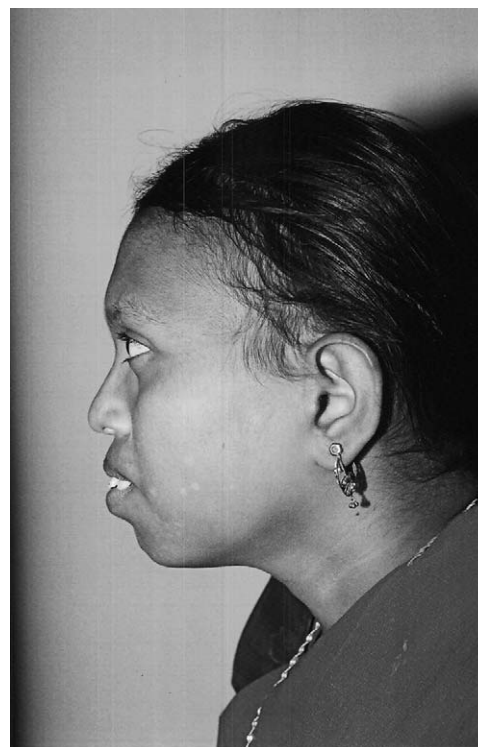
Front view of the proband showing overall facial features.

showing mild symmetrical T-wave inversions in the anterior leads (Fig. 4). Immunophenotyping of leukocytes did not reveal any autoimmune phenomena.

The proband's sister was 23 years old, has marked alopecia from the age of 13 years (Fig. 5, she wears a wig). She had primary amenorrhea with no response to hormone therapy. Her facial features were similar to the proband, she had few wisps of hair, no finger deformity and was intelligent. The rest of the physical examination was normal. She had impaired glucose tolerance with hypergonadotropic hypogonadism. Ultrasound of the abdomen did not show the uterus but small ovoid structures in the adenexa were present bilaterally, probably representing rudimentary ovaries.

The proband's brother was 19 years old. He had eunuchoid body proportions. He had significant alopecia and fixed flexion deformities of the fourth and fifth fingers in both hands. Examination of the hair did not show pilli torti. Hypogonadism was observed with testicular volume of 4 ml bilaterally with Tanner's Stage 1 pubic hair. His plasma glucose values were in the diabetic range. He had hypogonadotropic hypogonadism (FSH of 1.11 mIU/ml) in contrast to his sisters.

Fig. 2



Side view of the proband showing high forehead and malocclusion.

Fig. 3

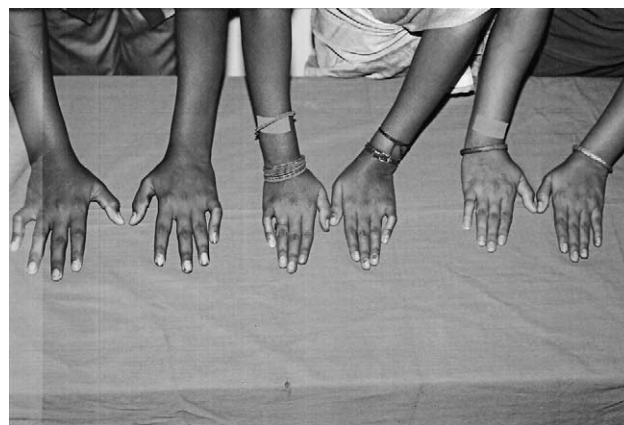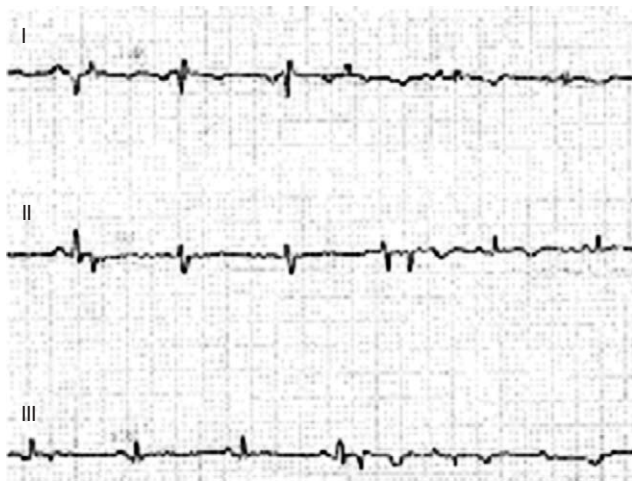


Photo shows large hands of the affected siblings. Note the deformity of the fingers, most prominent in the fifth finger.

Discussion

The family described here comprises three siblings with alopecia, hypogonadism and plasma glucose levels in the diabetic/prediabetic range. Woodhouse and Sakati (1983) have described the following features in six patients of two inbred Saudi Arabian families: hypogonadism,

Fig. 4



ECG showing T-wave inversion in the anterior leads.

Fig. 5



The family with three affected siblings and the parents. From left: mother, proband, father (at back), sister with wig and brother.

diabetes mellitus, very sparse scalp hair, eyebrows, mild mental retardation, mild sensorineural hearing loss and variations in the ST-T portions of the ECG. The proband in our family has all these features.

Her facial features are rounded and have striking similarity to the cases described by Oerter *et al.* (1992). They describe deformity of fifth finger in affected and unaffected sibs. In this family, the proband and her brother have fixed flexed deformity of fourth and fifth fingers. All three siblings have large hands. The proband and her sister have prominent upper incisors and malocclusion. Although the girls manifested with hypergonadotropic hypogonadism, the boy had hypogonadotropic hypogonadism. The proband developed thrombocytopenia not previously described. This could

Table 1 Comparison of previously described Woodhouse-Sakati syndromes

Clinical features	Woodhouse and Sakati (1983)	Oerter <i>et al.</i> (1992)	Gul <i>et al.</i> (2000)	Present paper (2007)
Alopecia	X	X	X	X
Deafness	X	X	X	X
Ocular manifestations	X			X
	Bilateral keratoconus (Al-Swailem <i>et al.</i> , 2006) in two original cases			Astigmatism, high myopia, divergent squint, amblyopia
Mental retardation	X	X	X	X
Hypogonadism	X	X	X	X
Diabetes mellitus	X	X	X	X
ECG abnormalities	X	X		X
[Idiopathic thrombocytopenic (purpura)]				X

X, feature present.

Woodhouse-Sakati syndrome features taken from LDDB.

Alopecia totalis.

Abnormal secondary sexual hair.

Deafness, sensorineural.

Absent eyebrows.

Absent or hypoplastic breasts.

ECG abnormality.

Hypogonadism.

Primary amenorrhea.

Late puberty in women.

Late puberty in men.

Large hands.

Diabetes mellitus.

be a chance event or part of the syndrome indicating a common genetic mechanism leading to alopecia, diabetes mellitus and thrombocytopenia.

A family described by Gul *et al.* (2000) mentions peripheral neuropathy and a dermal abnormality (pili annularis) as added features. Diabetes as a cause of peripheral neuropathy was probable. Our cases did not have any peripheral neuropathy or pili torti. Al-Swailem *et al.* (2006) reported bilateral keratoconus in the two originally described siblings by Woodhouse and Sakati in 1983. The proband in this study does not have keratoconus. A comparison of other cases of Woodhouse-Sakati syndrome is given in Table 1.

This report of three affected siblings with features of Woodhouse-Sakati is the first from India, and provides further evidence that it is a distinct genetic syndrome with autosomal-recessive inheritance. A phenotypic variability in the affected family members was observed. It is interesting to note that all these syndromes have been described in West Asian and Southeast Asian population that have a high coefficient of inbreeding.

Acknowledgements

The authors thank Dr Elizabeth Thompson MBBS, MD, FRACP Clinical Geneticist SA Clinical Genetics Service, Women's and Children's Hospital North Adelaide, South

Australia for her opinion and critical appraisal of the manuscript. They also thank the family for giving consent to publish photographs.

References

- Al-Swailem SA, Al-Assiri AA, Al-Torbak AA (2006). Woodhouse Sakati syndrome associated with bilateral keratoconus. *Br J Ophthalmol* **90**:116–117.
- Gul D, Ozata M, Mergen H, Odabasi Z, Mergen M (2000). Woodhouse and Sakati Syndrome (MIM 241080): report of a new patient. *Clin Dysmorphol* **9**:123–125.
- Oerter KE, Friedman TC, Anderson HC, Casserole FG (1992). Familial syndrome of endocrine and neuroectodermal abnormalities. *Am J Med Genet* **44**: 487–491.
- Woodhouse NJY, Sakati NA (1983). A syndrome of hypogonadism, alopecia, diabetes mellitus, mental retardation deafness and ECG abnormalities. *J Med Genet* **20**:216–219.